



**PATIENT**

Big Brown Bat  
11.18.22 Stevenson

**PRESENTING CLINICAL SIGNS**

P has been in captivity for 4 weeks after being rescued and has been vocal and reactive. Eating and drinking normally. No progression of signs consistent with rabies.  
Abnormal PE/Chem/CBC/UA Results: RH tibia has callus formation consistent with healing fracture. PE and oral exam under anesthesia were otherwise normal.

**SPECIES**

Bat

**COMPUTED TOMOGRAPHY OF THE ENTIRE BAT**

A high resolution plain CT study of the thorax and abdomen are provided for review.

**BREED**

Big Brown Bat

**COMPUTED TOMOGRAPHIC FINDINGS**

The bony and surrounding soft tissue structures are within normal limits.

The cardiovascular structures including the pulmonary vasculature are within normal limits.

The bronchial tree presents with regular branching and tapers uniformly towards the periphery as expected, the bronchial walls are thin and smooth. The bronchus-to-artery ratio is within normal limits.

**SEX**

M

The lung parenchyma presents the expected architecture and attenuation behavior.

**AGE**

1 Year

There is a lack of serosal peritoneal detail, effacing the margins of the abdominal organs.

A small amount of gas is seen throughout the gastrointestinal tract.

Moderate smooth callus formation is seen along the proximal segment of the right tibia.

**INTERPRETED BY**

Sebastian Schaub, DVM  
Dr. med. vet. DipECVDI

**COMPUTED TOMOGRAPHIC DIAGNOSIS**

- Chronic right proximal tibial fracture – in remodeling phase
- Normal thorax

**HOSPITAL NAME**

Petroglyph Animal  
Hospital

**INTERPRETATION OF THE FINDINGS & FURTHER RECOMMENDATIONS**

No significant abnormalities are appreciated, but the osseous remodeling of the right tibia indicative for chronic tibial fracture. Theoretically osteomyelitis is a consideration as well, but the odds are low.

**REFERRING VET**

Kariana Atkinson

**INVOICE**

55386

**DATE**

11-27-22



**PATIENT**

Big Brown Bat  
11.18.22 Stevenson

**SPECIES**

Bat

**BREED**

Big Brown Bat

**SEX**

M

**AGE**

1 Year

**INTERPRETED BY**

Sebastian Schaub, DVM  
Dr. med. vet. DipECVDI

**HOSPITAL NAME**

Petroglyph Animal  
Hospital

**REFERRING VET**

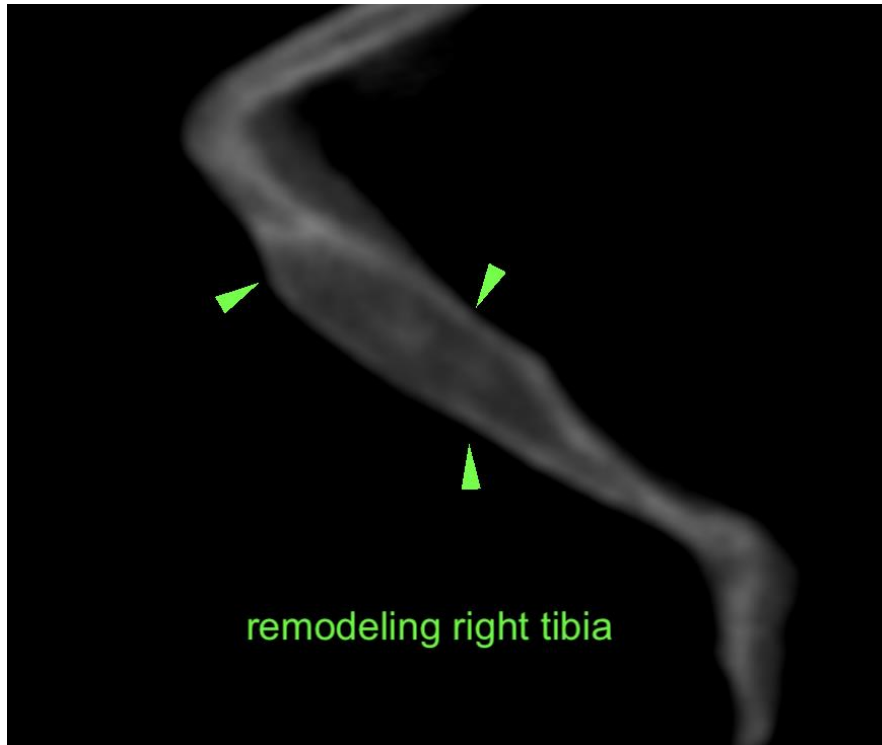
Kariana Atkinson

**INVOICE**

55386

**DATE**

11-27-22



The information and recommendations provided are based on the images presented by the referring veterinarian/sonographer. No evaluation can be communicated regarding pathology that was not visible in the image/video clips provided.

Thank you for this referral. If the clinical or image interpretation does not parallel your findings or if I can be of any further assistance please contact me.

**Sebastian Schaub**, Sebastian Schaub, DVM, Dr. med. vet. DipECVDI  
sebast.schaub@gmail.com