



PATIENT

Pierre Byrne

PRESENTING CLINICAL SIGNS

Rechecking: GI ISSUE History: P IS HERE FOR A RECHECK GI ISSUES, P WAS HERE ON WED FOR SOFT STOOL, P WAS FINE ON WED, THURSDAY P VOMITED FOOD AND 3X WHITE FOAM WITHIN 10 HOURS, P VOMITED YESTERDAY(FRIDAY), NO VOMITING TODAY STOOL IS BACK TO NORMAL INTERMITTENT VOMITING AND RARE DIARRHEA FOR THE PAST 2 YEARS. MRS FEEDS A VARIETY OF FOODS/SUPPLEMENTS AND CHANGES FOODS OFTEN BUT HAS BEEN RELIGIOUS WITH RC GI LOW FAT PAST FEW DAYS. NO VOMITING IN 36 HOURS.

SPECIES

Canine

BREED

French Bulldog

Abnormal PE/Chem/CBC/UA Results: Exam Notes: BAR, BCS 6/9, AB PALP WNL. H/L - REFERRED UPPER AIRWAY SOUNDS. Diagnostics & Testing: AB RADS - LIVER ON SMALL SIZE, NO HIATAL HERNIA, NO FB. CONSULT PENDING CBC/SUPERCHEM/LYTES - PENDING A: CHRONIC INTERMITTENT VOMITING/DIARRHEA - R/O DIETARY, IBD, ADDISONS, PANCREATITIS

SEX

Male

RADIOGRAPHIC STUDY OF THE ABDOMEN

Radiographs of the abdomen in two imaging planes are provided for review.

RADIOGRAPHIC FINDINGS

AGE

3 Years

T11 presents a wedge shaped vertebra body. L7 has a moderately foreshortened vertebral body.

No abnormalities of the extraabdominal soft tissues are noted. The abdominal wall is smooth and thin.

INTERPRETED BY

Sebastian Schaub, DVM
Dr. med. vet. DipECVDI

The serosal detail is maintained throughout the peritoneal and retroperitoneal space.

The liver is appropriate in position, size and presents uniform opacity.

HOSPITAL NAME

DPC Veterinary
Hospital

The splenic head is in the anticipated position and within normal limits for size and opacity. The splenic body and tail are considered normal for position, size, shape and opacity.

Both kidneys are seen and present with normal size, shape, delineation and opacity. The urinary bladder is in its anticipated position. No radiopaque calculi are noted throughout the upper and lower urinary tract.

REFERRING VET

Dr. Feldt

The stomach is in its anticipated position and is moderately distended by gas and fluid.

The small intestinal loops are of even diameter and non-dilated, a small amount of gas is seen within the small intestinal loops and considered within normal limits.

INVOICE

48608

The colon is seen in the expected position and presents with appropriate content.

RADIOGRAPHIC DIAGNOSIS

DATE

11-27-21

- Mild to moderate gas and fluid distended stomach



PATIENT

Pierre Byrne

SPECIES

Canine

BREED

French Bulldog

SEX

Male

AGE

3 Years

INTERPRETED BY

Sebastian Schaub, DVM
Dr. med. vet. DipECVDI

HOSPITAL NAME

DPC Veterinary
Hospital

REFERRING VET

Dr. Feldt

INVOICE

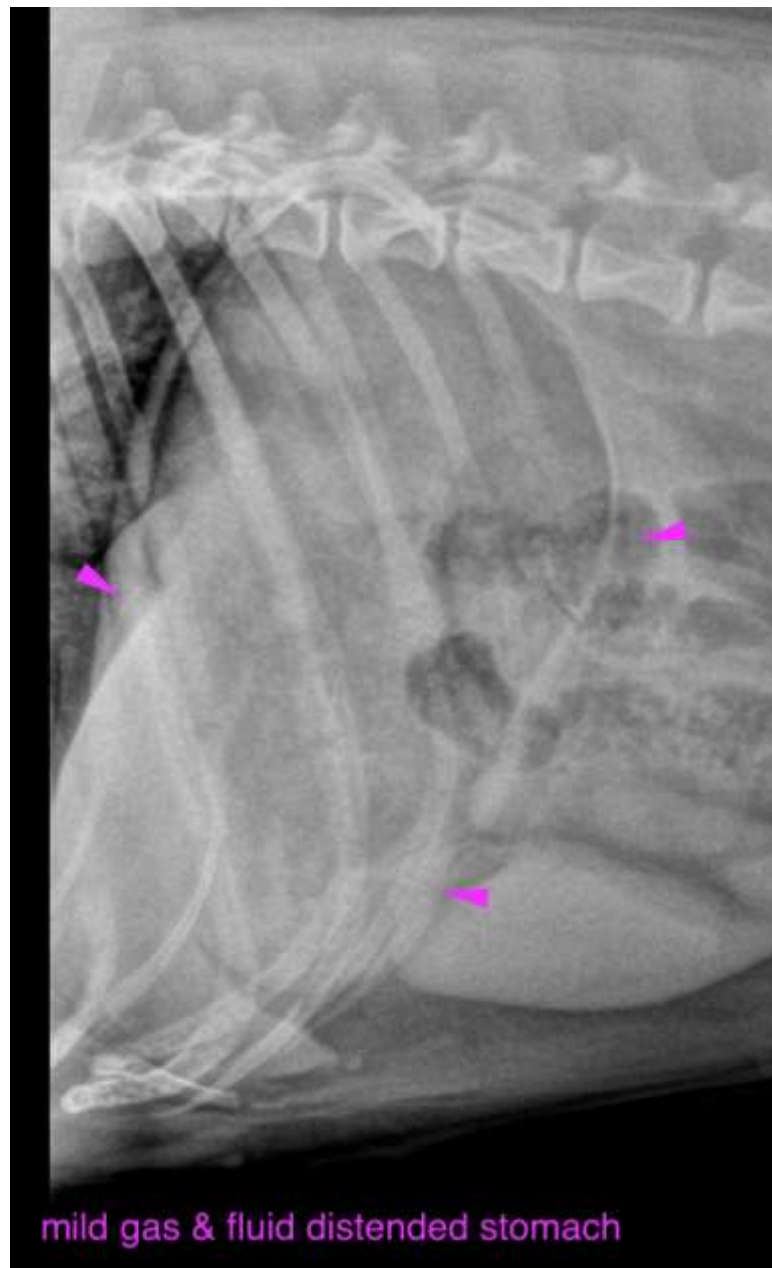
48608

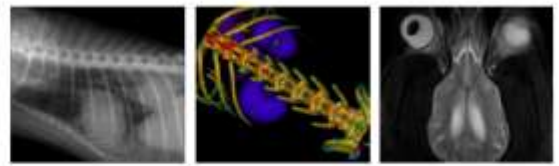
DATE

11-27-21

INTERPRETATION OF THE FINDINGS & FURTHER RECOMMENDATIONS

The radiographic study presents no abnormality, explaining the current gastrointestinal clinical signs and the presumptive diagnosis is gastroenteritis. There is no evidence of radiopaque foreign material or signs for gastrointestinal mechanical obstruction. If not done so yet, complementing workup by complete blood work including cpl appears beneficial. If clinical signs are refractory to therapy, recommend follow up radiographs or a complete abdominal ultrasound examination; in some cases, a high ileus may lack classical radiographic signs of mechanical obstruction.





PATIENT

Pierre Byrne

The information and recommendations provided are based on the images presented by the referring veterinarian. No evaluation can be communicated regarding pathology that was not visible in the image/video clips provided.

SPECIES

Canine

Thank you for this referral. If the clinical or image interpretation does not parallel your findings or if I can be of any further assistance please contact me.

BREED

French Bulldog

Sebastian Schaub, Sebastian Schaub, DVM, Dr. med. vet. DipECVDI
sebast.schaub@gmail.com

SEX

Male

AGE

3 Years

INTERPRETED BY

Sebastian Schaub, DVM
Dr. med. vet. DipECVDI

HOSPITAL NAME

DPC Veterinary
Hospital

REFERRING VET

Dr. Feldt

INVOICE

48608

DATE

11-27-21