



**PATIENT**

Lola Wu

**PRESENTING CLINICAL SIGNS**

Here for an exam and blood work On same dose of Pred 5mg once a day gets B12 biweekly for the past 4 injection  
 Abnormal PE/Chem/CBC/UA Results: Vit B12 level to lab- Pending Diag- WNL CBC- WNL Vit B12 0.25ml SQ

**SPECIES**

Canine

**RADIOGRAPHIC STUDY OF THE THORAX & ABDOMEN**

A complete set of radiographs of the thorax and abdomen is provided for review.

**BREED**

Yorkshire Terrier

**RADIOGRAPHIC FINDINGS**

Thorax

**SEX**

Female

The surrounding bony structures are within normal limits.

The extrathoracic soft tissues present homogeneous without abnormalities.

**AGE**

7 Years

The heart is of normal size and shape, there is no evidence of cardiac chamber or vascular enlargement. The pulmonary vasculature is within normal limits.

The cranial mediastinum presents the expected soft tissue opacity. The mediastinal width is less than twice the width of the vertebral column at the same level.

**INTERPRETED BY**

Sebastian Schaub, DVM  
 Dr. med. vet. DipECVDI

The trachea is normal in diameter and presents the anticipated course. The luminal outline of the trachea is smooth.

The bronchial tree presents with thin walls and tapers uniformly towards the periphery as expected.

**HOSPITAL NAME**

Animal Paradise  
 Hospital

The lung parenchyma presents the expected architecture and opacity; the intrapulmonary vascular branching is seen up to the third order lung vessels.

The diaphragm is well delineated with even surface and the expected mild cranial bulging of the diaphragmatic cupola.

**REFERRING VET**

Dr. Elshafie

Abdomen

The patella of the stifle joints bilaterally is superimposed on the medial femoral condyle.

**INVOICE**

48609

No abnormalities of the extraabdominal soft tissues are noted. The abdominal wall is smooth and thin.

The serosal detail is maintained throughout the peritoneal and retroperitoneal space.

**DATE**

11-27-21

The hepatic volume is mild to moderately increased and the caudoventral margins of the liver are mildly rounded.

The splenic head is in the anticipated position and within normal limits for size and opacity.



**PATIENT**

Lola Wu

Both kidneys are seen and present with normal size, shape, delineation and opacity. The urinary bladder is in its anticipated position. No radiopaque calculi are noted throughout the upper and lower urinary tract.

The stomach is in its anticipated position and presents normal content.

**SPECIES**

Canine

The small intestinal loops are of even diameter and non-dilated, a small amount of gas is seen within the small intestinal loops and considered within normal limits.

The colon is seen in the expected position and presents with appropriate content.

**BREED**

Yorkshire Terrier

**RADIOGRAPHIC DIAGNOSIS**

- Mild hepatomegaly
- Bilateral medial patellar luxation – likely incidental due to lack of clinical signs
- Normal thorax

**SEX**

Female

**INTERPRETATION OF THE FINDINGS & FURTHER RECOMMENDATIONS**

Potentials for the hepatomegaly include metabolic hepatic disease/steroid induced hepatopathy, hepatitis or neoplastic infiltration. Ultrasound including FNA sampling can be used as minimally advanced diagnostic tests.

**AGE**

7 Years

**INTERPRETED BY**

Sebastian Schaub, DVM  
Dr. med. vet. DipECVDI

**HOSPITAL NAME**

Animal Paradise  
Hospital

**REFERRING VET**

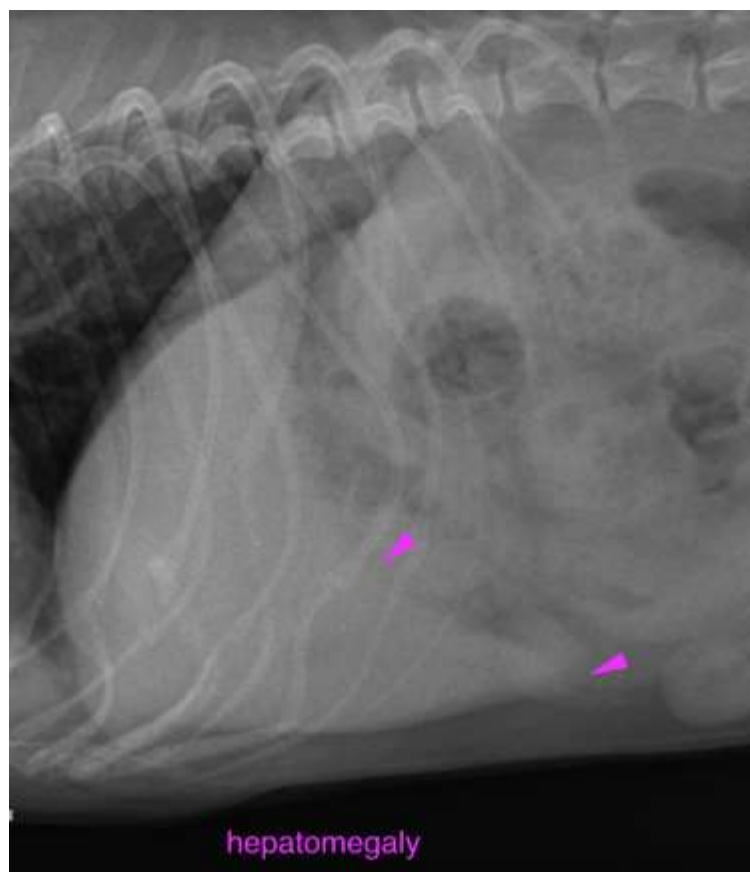
Dr. Elshafie

**INVOICE**

48609

**DATE**

11-27-21





**PATIENT**

Lola Wu

**SPECIES**

Canine

**BREED**

Yorkshire Terrier

**SEX**

Female

**AGE**

7 Years

**INTERPRETED BY**

Sebastian Schaub, DVM  
Dr. med. vet. DipECVDI

**HOSPITAL NAME**

Animal Paradise  
Hospital

**REFERRING VET**

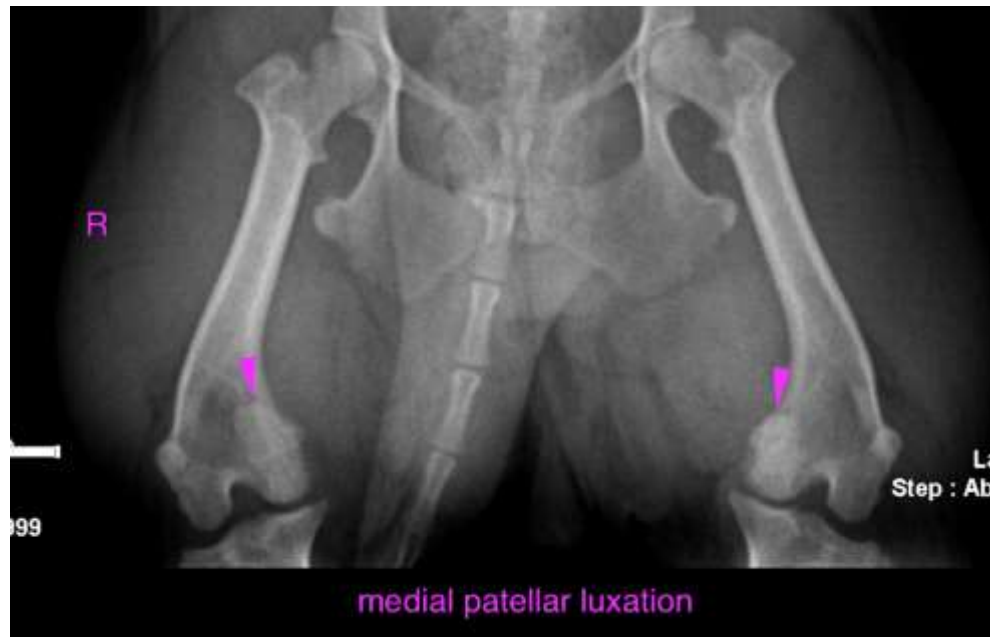Dr. Elshafie

**INVOICE**

48609

**DATE**

11-27-21



The information and recommendations provided are based on the images presented by the referring veterinarian. No evaluation can be communicated regarding pathology that was not visible in the image/video clips provided.

Thank you for this referral. If the clinical or image interpretation does not parallel your findings or if I can be of any further assistance please contact me.

**Sebastian Schaub**, Sebastian Schaub, DVM, Dr. med. vet. DipECVDI  
sebast.schaub@gmail.com