



PATIENT

Dina Mazuera

PRESENTING CLINICAL SIGNS

P is here to check left back leg O says P was playing and jumping around and hurt herself.
 Abnormal PE/Chem/CBC/UA Results: Adequan 0.5 ml IM Rimadyl 12mg SQ disp Rimadyl 25mg 1/2 tab BID for 10 days

SPECIES

Canine

RADIOGRAPHIC STUDY OF THE PELVIS AND STIFLE JOINTS

A complete set of radiographs of the pelvis and the left stifle joint is provided for review.

BREED

Poodle

RADIOGRAPHIC FINDINGS

The osseous and surrounding soft tissue structures of the pelvis – including the coxofemoral joints – are within normal limits.

SEX

FS

The patella of the left stifle joint is seen medial to the medial femoral condyle. The left stifle joint presents a mild intracapsular swelling. The periarticular bones of both stifle joints present mild osteophyte new bone formation.

RADIOGRAPHIC DIAGNOSIS

- Left sided medial patellar luxation
- Mild to moderate articular swelling left stifle joint
- Mild degenerative osteoarthritis stifle joints bilaterally
- Normal pelvis & coxofemoral joints

AGE

10 Years

INTERPRETED BY

Sebastian Schaub, DVM
 Dr. med. vet. DipECVDI

INTERPRETATION OF THE FINDINGS & FURTHER RECOMMENDATIONS

There is left sided medial patellar luxation which can be a cause for lameness. However, due to the acute onset of clinical signs other potentials such as pathology of the cranial cruciate ligament, contusion/distortion need to be considered as potentials. Check if a positive drawer sign or tibial compression test is present. A clinical trial with rest and NSAIDs can be tried in first instance. If there is suspicion for the medial patellar luxation being the primary cause for the clinical signs, surgical correction should be considered.

HOSPITAL NAME

Animal Paradise Hospital

REFERRING VET

Dr. Elshafie

INVOICE

48610

DATE

11-27-21



PATIENT

Dina Mazuera

SPECIES

Canine

BREED

Poodle

SEX

FS

AGE

10 Years

INTERPRETED BY

Sebastian Schaub, DVM
Dr. med. vet. DipECVDI

HOSPITAL NAME

Animal Paradise
Hospital

REFERRING VET

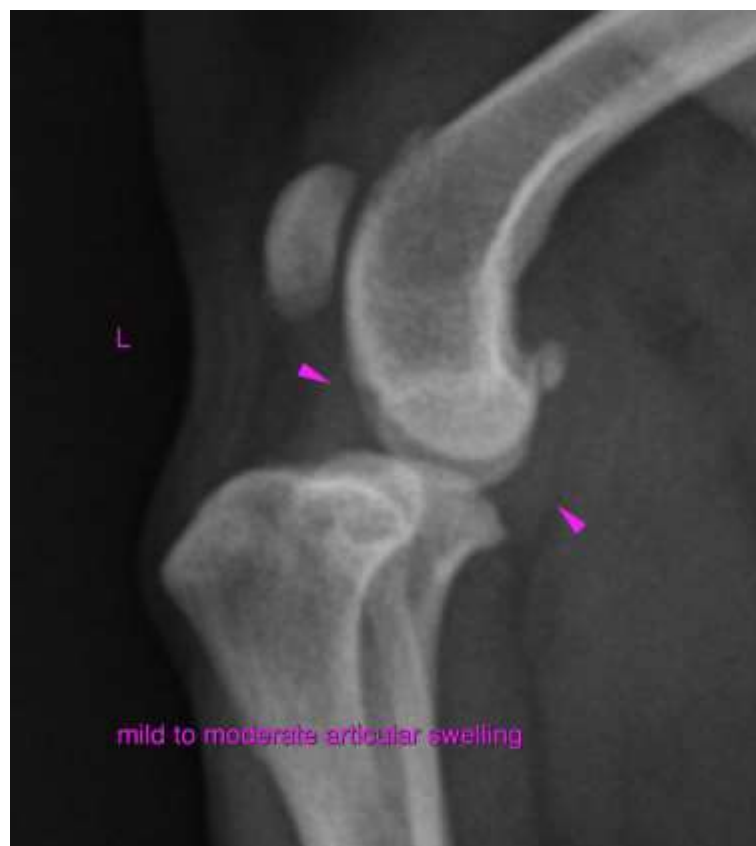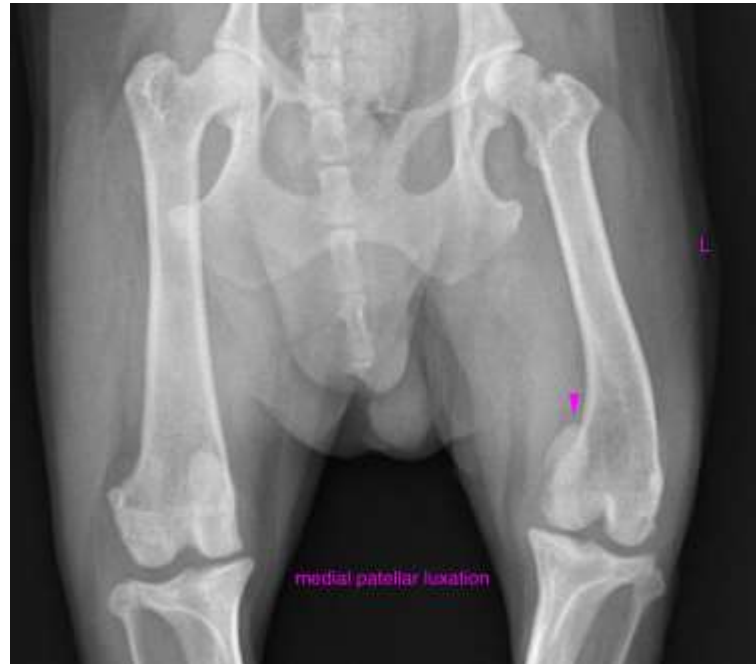Dr. Elshafie

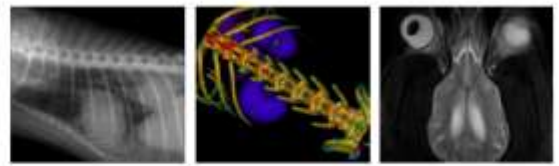
INVOICE

48610

DATE

11-27-21





PATIENT

Dina Mazuera

The information and recommendations provided are based on the images presented by the referring veterinarian. No evaluation can be communicated regarding pathology that was not visible in the image/video clips provided.

Thank you for this referral. If the clinical or image interpretation does not parallel your findings or if I can be of any further assistance please contact me.

SPECIES

Canine

Sebastian Schaub, Sebastian Schaub, DVM, Dr. med. vet. DipECVDI
sebast.schaub@gmail.com

BREED

Poodle

SEX

FS

AGE

10 Years

INTERPRETED BY

Sebastian Schaub, DVM
Dr. med. vet. DipECVDI

HOSPITAL NAME

Animal Paradise
Hospital

REFERRING VET

Dr. Elshafie

INVOICE

48610

DATE

11-27-21