



PATIENT

Neptune El Mugammar

SPECIES

Feline

BREED

Maine Coon

SEX

MN

AGE

23M

WEIGHT

7.1

INTERPRETED BY

Sebastian Schaub, DVM
Dr. med. vet.
DipECVDI

IMAGING PERFORMED BY

Dr. Kamila Pichova

HOSPITAL NAME

Balmy Beach Pet
Hospital

REFERRING VET

Dr. Kamila Pichova

INVOICE

72773

DATE

11-26-25

PRESENTING CLINICAL SIGNS

The respiratory episodes are described by the owner as sporadic, occurring approximately q 10 to 14 days. They are characterized as wheezing or gagging attacks that last for a while, rather than a simple cough. These events are often triggered by exertion, such as after chasing the other cat in the household. During these episodes, he makes a gagging sound at the end but does not produce any vomit or spit. In the last week, one such episode was observed
Abnormal PE/Chem/CBC/UA Results: No abnormalities on CBC, Chem or PE UA abnormalities: pH 8, USG:1018

RADIOGRAPHIC STUDY OF THE THORAX

Radiographs of the thorax in three imaging planes are provided for review.

RADIOGRAPHIC FINDINGS

The surrounding bony structures are within normal limits.

The extrathoracic soft tissues present homogeneous without abnormalities.

The vertebral heart score is 7.1 (normal ≤ 8.2). In the VD view the heart is occupying approximately 80% of the thoracic width. pulmonary vasculature is within normal limits.

The trachea is normal in diameter and presents the anticipated course. The luminal outline of the trachea is smooth.

The bronchial tree presents with thin walls and tapers uniformly towards the periphery as expected.

The lung parenchyma presents the expected architecture and opacity; the intrapulmonary vascular branching is seen up to the third order lung vessels.

The diaphragm is well delineated with even surface and the expected mild cranial bulging of the diaphragmatic cupola.

RADIOGRAPHIC DIAGNOSIS

- Equivocal cardiomegaly

INTERPRETATION OF THE FINDINGS & FURTHER RECOMMENDATIONS

The heart is subjectively prominent, although the vertebral heart score is within normal limits. I consider the odds for cardiac disease low, however workup may be complemented by a cardiac echo to rule out congenital heart disease cardiomyopathy entirely.

No abnormalities of the lower airways are appreciated.



PATIENT

Neptune El Mugammar

SPECIES

Feline

BREED

Maine Coon

SEX

MN

AGE

23M

WEIGHT

7.1

INTERPRETED BY

Sebastian Schaub, DVM
Dr. med. vet.
DipECVDI

IMAGING PERFORMED BY

Dr. Kamila Pichova

HOSPITAL NAME

Balmy Beach Pet
Hospital

REFERRING VET

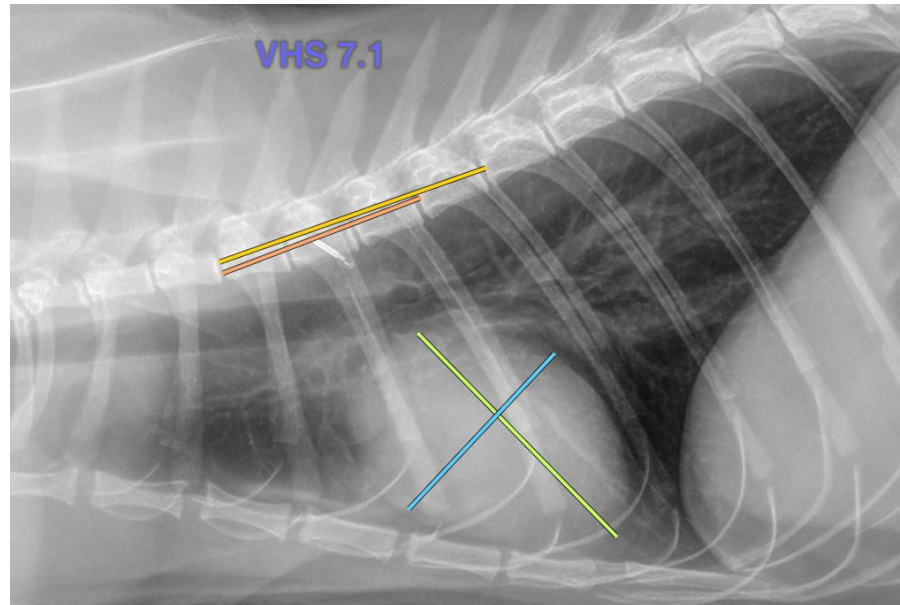
Dr. Kamila Pichova

INVOICE

72773

DATE

11-26-25



The information and recommendations provided are based on the images presented by the referring veterinarian/sonographer. No evaluation can be communicated regarding pathology that was not visible in the image/video clips provided.

Thank you for this referral. If the clinical or image interpretation does not parallel your findings or if I can be of any further assistance please contact me.

Sebastian Schaub, Sebastian Schaub, DVM, Dr. med. vet. DipECVDI
info@sonopath.com