

**PATIENT**

Lola Baker

PRESENTING CLINICAL SIGNS

Last 3 days been very sore, reluctant to place wt on left hind, historically a little stiff first thing in AM. Abnormal PE/Chem/CBC/UA Results: toe touch lameness in LH, dec rom in both hips, sore to spinal palp, cp maybe slightly delayed in LH, but inconsistent. hopping okay but delay slight in LH but inconsist. . reflex wnl, p painful to palp of muscle of LH thigh.

SPECIES

Canine

RADIOGRAPHIC STUDY OF THE LUMBAR SPINE & PELVIS

Radiographs of the lumbar spine & pelvis in two imaging planes are provided for review.

BREEDPortuguese Water
Dog**RADIOGRAPHIC FINDINGS**

Generalized moderate to marked bridging spondylosis formation is present along the lumbar spine. The lateral spondylosis are multifocally superimposed on the neuroforamen.

SEX

SF

Both coxofemoral joints present moderate osteophyte new bone formation. The joint space of the coxofemoral joints bilaterally is incongruent. The acetabular groove bilaterally is shallow, and the center of the femoral heads is lateral to the dorsal acetabular rim.

RADIOGRAPHIC DIAGNOSIS

- Moderate degenerative osteoarthritis coxofemoral joints bilaterally, due to hip dysplasia
- Advanced spondylosis formation along the lumbar spine

AGE

11 Years, 1 Month

INTERPRETATION OF THE FINDINGS & FURTHER RECOMMENDATIONS**INTERPRETED BY**Sebastian Schaub, DVM
Dr. med. vet. DipECVDI

The main finding is advanced spondylosis formation along the lumbar spine and degenerative osteoarthritis of the coxofemoral joints bilaterally. An acute or chronic insult may have caused acute onset of clinical signs. To rule in/out accompanying discopathy cross-sectional imaging is warranted. A clinical trial with rest and pain management is a consideration as well.

HOSPITAL NAMEGrove Veterinary
Clinic**REFERRING VET**

Dr. Burton

INVOICE

48598

DATE

11-26-21



PATIENT

Lola Baker

SPECIES

Canine

BREED

Portuguese Water
Dog

SEX

SF

AGE

11 Years, 1 Month

INTERPRETED BY

Sebastian Schaub, DVM
Dr. med. vet. DipECVDI

HOSPITAL NAME

Grove Veterinary
Clinic

REFERRING VET

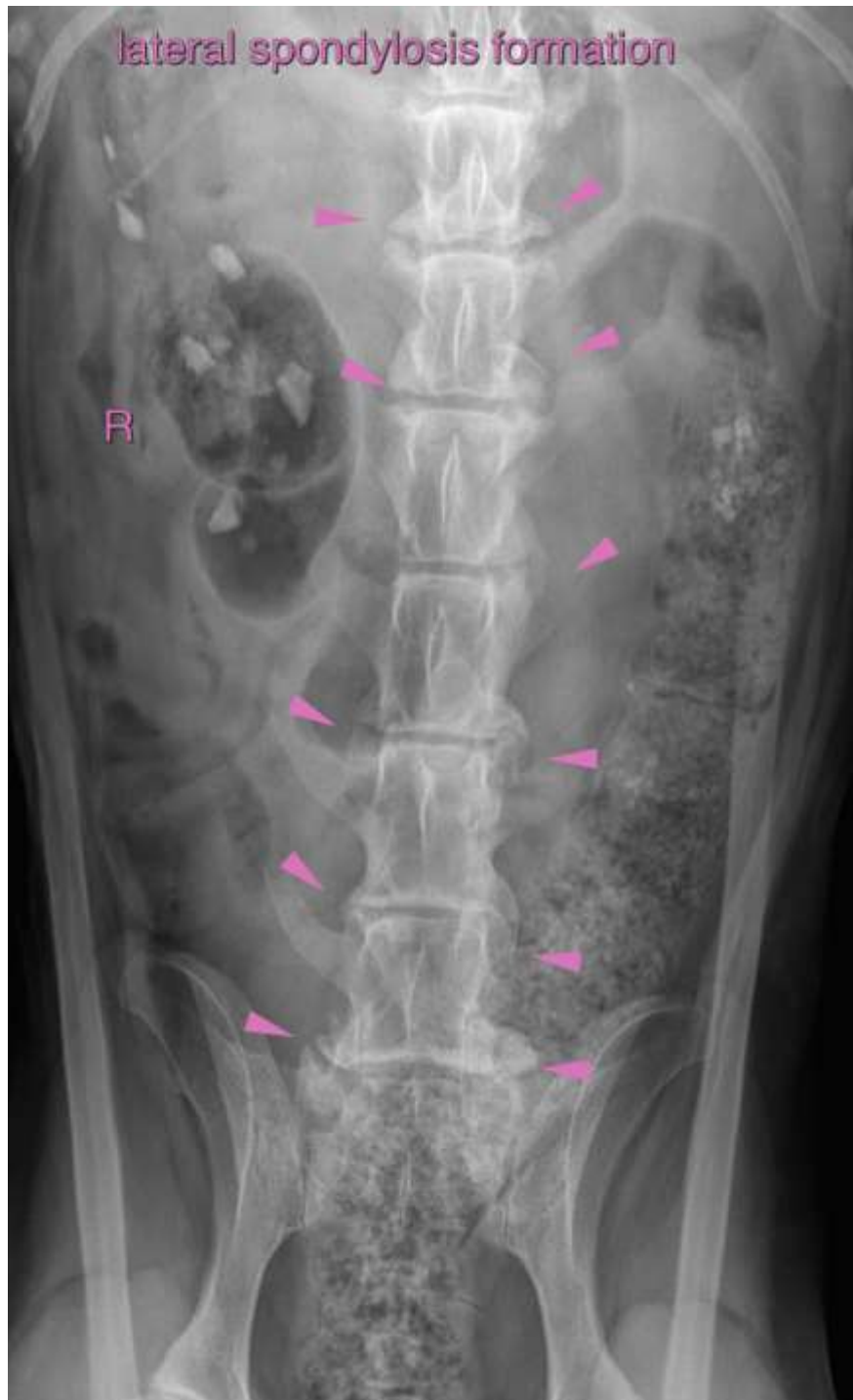
Dr. Burton

INVOICE

48598

DATE

11-26-21





PATIENT

Lola Baker

SPECIES

Canine

BREED

Portuguese Water
Dog

SEX

SF

AGE

11 Years, 1 Month

INTERPRETED BY

Sebastian Schaub, DVM
Dr. med. vet. DipECVDI

HOSPITAL NAME

Grove Veterinary
Clinic

REFERRING VET

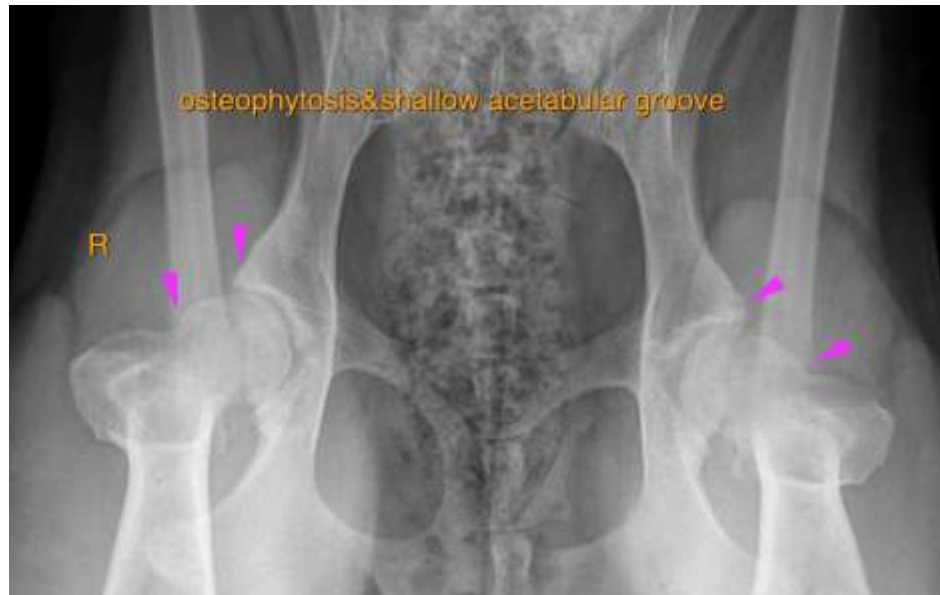Dr. Burton

INVOICE

48598

DATE

11-26-21



The information and recommendations provided are based on the images presented by the referring veterinarian. No evaluation can be communicated regarding pathology that was not visible in the image/video clips provided.

Thank you for this referral. If the clinical or image interpretation does not parallel your findings or if I can be of any further assistance please contact me.

Sebastian Schaub, Sebastian Schaub, DVM, Dr. med. vet. DipECVDI
sebast.schaub@gmail.com