

PATIENT

Violet Chavez

SPECIES

Canine

BREED

Australian Shepherd

SEX

FS

AGE

12

WEIGHT

41

INTERPRETED BY

Sebastian Schaub, DVM
Dr. med. vet.
DipECVDI

IMAGING PERFORMED BY

Veterinary Technicians

HOSPITAL NAME

Northshore Veterinary
Hospital

REFERRING VET

Caley Howard

INVOICE

72763

DATE

11-25-25

PRESENTING CLINICAL SIGNS

Intermittent vomiting starting last week, good appetite/energy has been maintained. Hematemesis on Sunday and then again this AM (quite bloody and gelatinous). 5# weight loss in the last 6 months. No diarrhea

Abnormal PE/Chem/CBC/UA Results: Normal exam. cbc/chem/t4/pli pending Sent home with supportive care Considering endoscopy next week if indicated

RADIOGRAPHIC STUDY OF THE ABDOMEN

Radiographs of the abdomen in three imaging planes are provided for review.

RADIOGRAPHIC FINDINGS

The surrounding bony structures are within normal limits.

No abnormalities of the extraabdominal soft tissues are noted. The abdominal wall is smooth and thin.

The serosal detail is maintained throughout the peritoneal and retroperitoneal space.

The liver is appropriate in position, size and presents uniform opacity.

The splenic head is in the anticipated position and within normal limits for size and opacity. The splenic body and tail are considered normal for position, size, shape and opacity.

Both kidneys are seen and present with normal size, shape, delineation and opacity. The urinary bladder is in its anticipated position. No radiopaque calculi are noted throughout the upper and lower urinary tract.

The stomach is in its anticipated position and is empty.

The small intestinal loops are of even diameter and non-dilated, a small amount of gas is seen within the small intestinal loops and considered within normal limits.

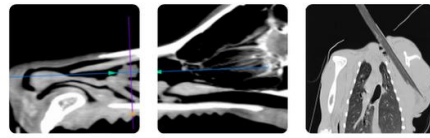
The colon is seen in the expected position and presents with appropriate content.

RADIOGRAPHIC DIAGNOSIS

- Overall empty gastrointestinal tract

INTERPRETATION OF THE FINDINGS & FURTHER RECOMMENDATIONS

An underlying cause for the intermittent vomiting cannot be specified. There is no evidence of radiopaque foreign material, abnormal gas pattern or signs for gastrointestinal mechanical obstruction.



PATIENT

Violet Chavez

SPECIES

Canine

BREED

Australian Shepherd

SEX

FS

AGE

12

WEIGHT

41

INTERPRETED BY

Sebastian Schaub, DVM
Dr. med. vet.
DipECVDI

IMAGING PERFORMED BY

Veterinary Technicians

HOSPITAL NAME

Northshore Veterinary
Hospital

REFERRING VET

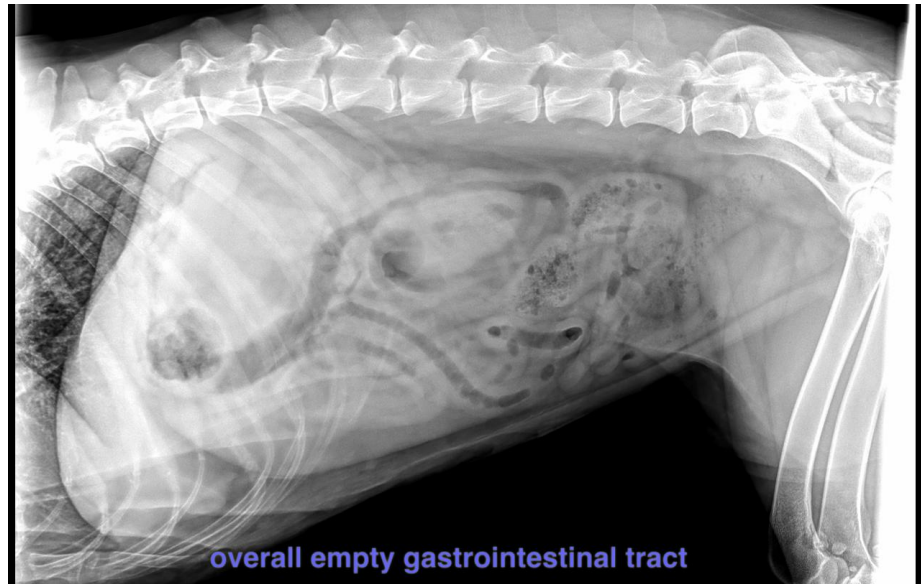Caley Howard

INVOICE

72763

DATE

11-25-25



The information and recommendations provided are based on the images presented by the referring veterinarian/sonographer. No evaluation can be communicated regarding pathology that was not visible in the image/video clips provided.

Thank you for this referral. If the clinical or image interpretation does not parallel your findings or if I can be of any further assistance please contact me.

Sebastian Schaub, Sebastian Schaub, DVM, Dr. med. vet. DipECVDI
info@sonopath.com