


PATIENT PRESENTING CLINICAL SIGNS

PATIENT Darcie Wilson

SPECIES Feline

BREED DSH

Mentation: Mentally inappropriate but responsive to auditory, tactile stimuli. Unable to tract moving objects. Cranial nerve exam: Absent menace OU. Mild asymmetrical pupils. Normal PLR and normal palpebral OU. Otherwise unremarkable. Gait/posture: Compulsive pacing in non-specific directions with no ataxia or paresis. Postural reactions: Proprioceptive positioning and hopping were normal in all limbs. Spinal reflexes: Normal. Sensory/nociception: Moderate hyperesthesia elicited with palpation along the cranium She was presented to the emergency clinic on November 21 2021 for possible vision loss. At that time she was continuing to be restless at home, spending most of her time pacing the house and having trouble finding food and water bowls. She does not bump into things but walks off surfaces and stare at walls. No vomiting or diarrhea was noted. If she finds her food bowl, she will eat her food. She does get stuck in corners. She still responds to any external stimuli, but is otherwise quiet. Her personality has changed overall.

MAGNETIC RESONANCE IMAGING OF THE SKULL

SEX Spayed Female

T2 weighted, FLAIR, diffusion weighted, SWI, T1 pre- and post-gadolinium sequence in multiple imaging planes are provided for review.

MAGNETIC RESONANCE IMAGING FINDINGS

AGE 10 Years

On the left side of the falx cerebri, attached to the falx/parietal bone, a well-defined, T2 peripheral isointense and central T2 hyperintense, FLAIR central mild hypointense, roundish mass is visible, measuring approximately 10 x 10 x 15 mm in size. There is a multiloculated T2 hyperintense eccentric rostroventral protrusion from the mass. The right parietal lobe is markedly distorted by the mass effect and a midline shift of the brain to the right is seen. The right cerebral hemisphere presents a diffuse T2 & FLAIR hyperintense signal. There is subtentorial herniation of the occipital lobe with mass effect on the cerebellum. Moderate herniation of the cerebellum into the foramen magnum is seen. Post contrast administration the mass is moderately contrast enhancing but the T2 hyperintense regions - presenting peripheral thin contrast enhancing wall.

INTERPRETED BY

Sebastian Schaub,
DVM Dr. med. vet.
DipECVDI

The ventricular system presents the expected dimensions, morphology and the CSF signal is within normal limits in all sequences.

HOSPITAL NAME

Animal Health
Partners

The tympanic bullae are aerated and the bony lining is thin.

Surrounding soft tissue structures in the head region are within normal limits.

REFERRING VET

Dr. Little

MAGNETIC RESONANCE IMAGING DIAGNOSIS

- Intracranial extraaxial cystic mass left side to the falx cerebri, level with the parietal lobe
- Evidence of intracranial hypertension with subtentorial herniation of the telencephalon and herniation of the cerebellum into the foramen magnum
- Secondary edema of the left cerebral hemisphere

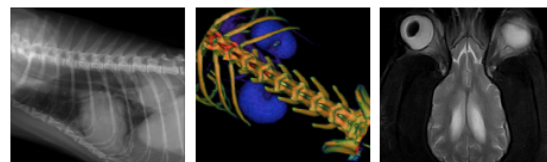
INVOICE

33092

INTERPRETATION OF THE FINDINGS & FURTHER RECOMMENDATIONS
DATE

11/25/21

The intracranial mass is most consistent with cystic meningioma and secondary mass effect on the brain and vasogenic edema and evidence of intracranial hypertension. The latter is degrading the prognosis. However, the chances of surgical excision of the mass might be discussed with neurologist.



PATIENT

Darcie Wilson

SPECIES

Feline

BREED

DSH

SEX

Spayed Female

AGE

10 Years

INTERPRETED BY

Sebastian Schaub,
DVM Dr. med. vet.
DipECVDI

HOSPITAL NAME

Animal Health
Partners

REFERRING VET

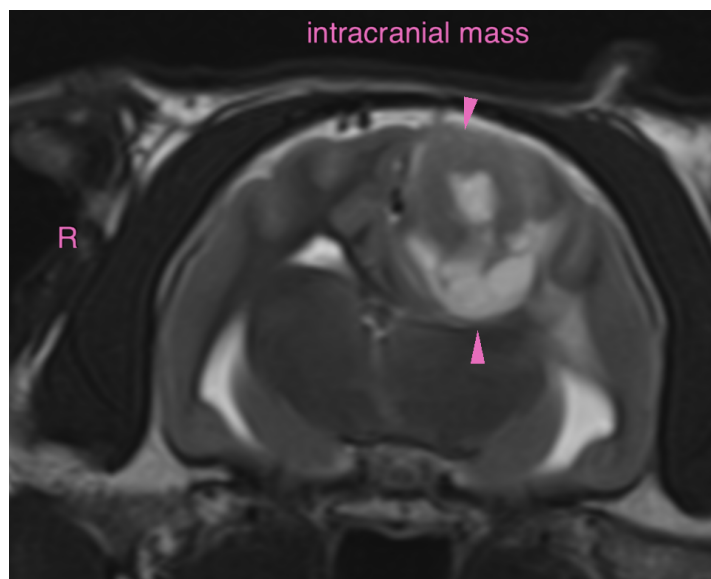
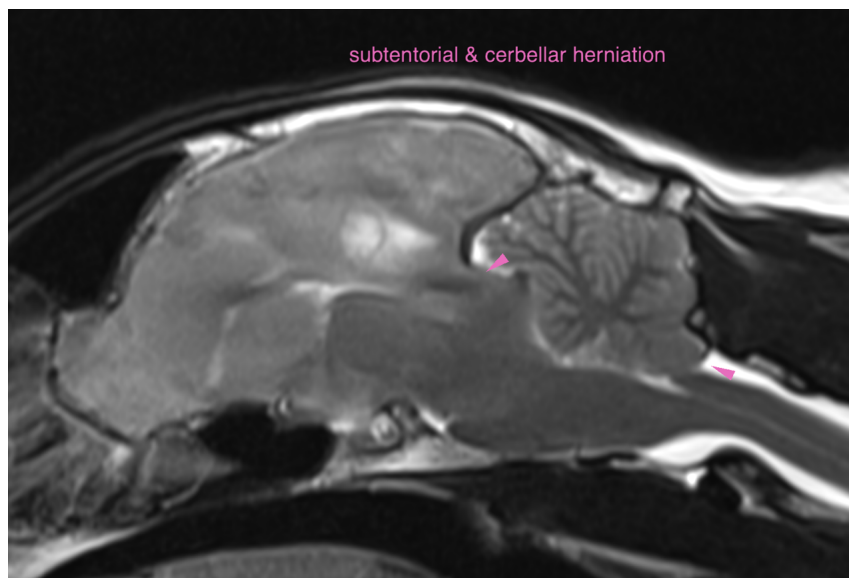
Dr. Little

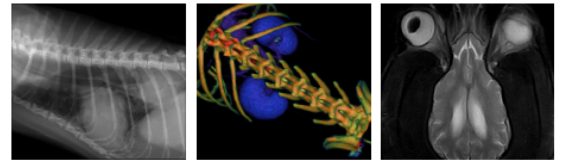
INVOICE

33092

DATE

11/25/21





PATIENT

Darcie Wilson

SPECIES

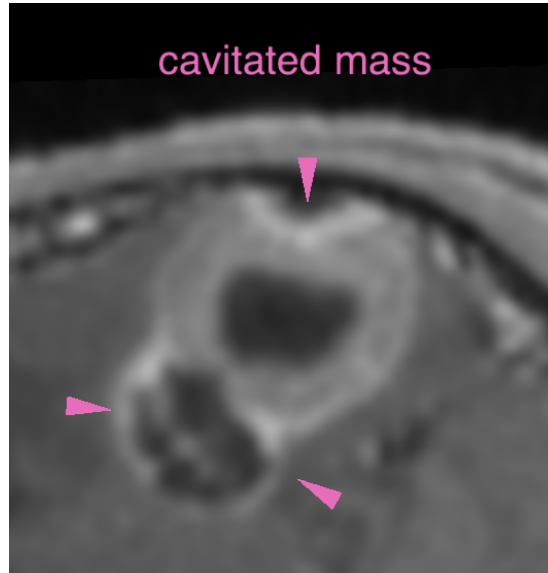
Feline

BREED

DSH

SEX

Spayed Female



AGE

10 Years

The information and recommendations provided are based on the images presented by the referring veterinarian. No evaluation can be communicated regarding pathology that was not visible in the image/video clips provided.

INTERPRETED BY

Sebastian Schaub,
DVM Dr. med. vet.
DipECVDI

Thank you for this referral. If the clinical or image interpretation does not parallel your findings or if I can be of any further assistance please contact me.

Sebastian Schaub, Sebastian Schaub, DVM, Dr. med. vet. DipECVDI
sebast.schaub@gmail.com

HOSPITAL NAME

Animal Health
Partners

REFERRING VET

Dr. Little

INVOICE

33092

DATE

11/25/21