


PATIENT PRESENTING CLINICAL SIGNS

CindyLooHou Garrison This morning pets left eye is swollen shut and painful, Pet also has a head tilt. Owner is unsure what happened. Pet has been E/D normal previously.

Abnormal PE/Chem/CBC/UA Results: Labwork was normal except for elevated white blood cells

SPECIES COMPUTED TOMOGRAPHIC STUDY OF THE SKULL

Canine A high resolution pre- and post-contrast CT study of the skull is provided for review.

BREED COMPUTED TOMOGRAPHIC FINDINGS

Catahoula Leopard Dog The pictured parts of the dentition are complete and unremarkable in all jaw quadrants.

The nasal cavity presents the expected aerated spaces between thin & even conchae and turbinates with smooth mucosal lining.

SEX The left ocular bulb is displaced dorsally and rostrally. Caudal to the left ocular bulb a mild ill-defined uniform soft tissue swelling is visible. Mild to moderate swelling of the eyelids is visible.

Spayed Female

Both temporomandibular joints present congruent joint spaces with even subchondral bone surfaces and are considered within normal limits.

AGE

2 Years Both tympanic bullae are aerated, the mucosal lining is not seen, the bony wall is smooth and thin. The external ear canals are within normal limits.

The left mandibular lymph nodes are prominent and uniform soft tissue attenuating.

INTERPRETED BY

Sebastian Schaub,
DVM Dr. med. vet.
DipECVDI

COMPUTED TOMOGRAPHIC DIAGNOSIS

- Left sided retrobulbar swelling and edema of the periorbital subcutaneous soft tissues
- Left sided exophthalmos
- Lymphadenopathy left mandibular lymph nodes
- No evidence of otitis media

HOSPITAL NAME

Wilvet Salem

INTERPRETATION OF THE FINDINGS & FURTHER RECOMMENDATIONS

The left sided exophthalmos, left sided retrobulbar swelling and the lymphadenopathy of the ipsilateral mandibular lymph nodes are supporting the diagnosis of retrobulbar abscess formation/steatitis. Unfortunately, in the plain CT study no additional information can be provided. Theoretically an inflammatory pseudotumor, granuloma (e.g. mycotic) or less likely neoplasia are differentials. Ultrasound might be used to screen for retroorbital fluid warranting surgical intervention.

REFERRING VET

Dr. Kristin Peterson

INVOICE

33097

DATE

11/25/21



PATIENT

CindyLooHou
Garrison

SPECIES

Canine

BREED

Catahoula Leopard
Dog

SEX

Spayed Female

AGE

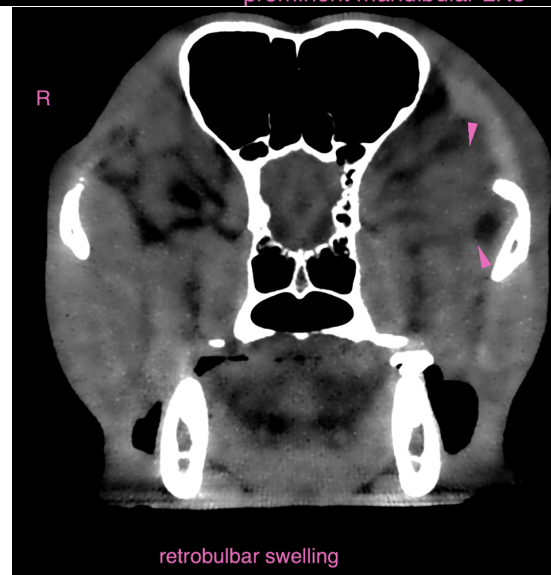
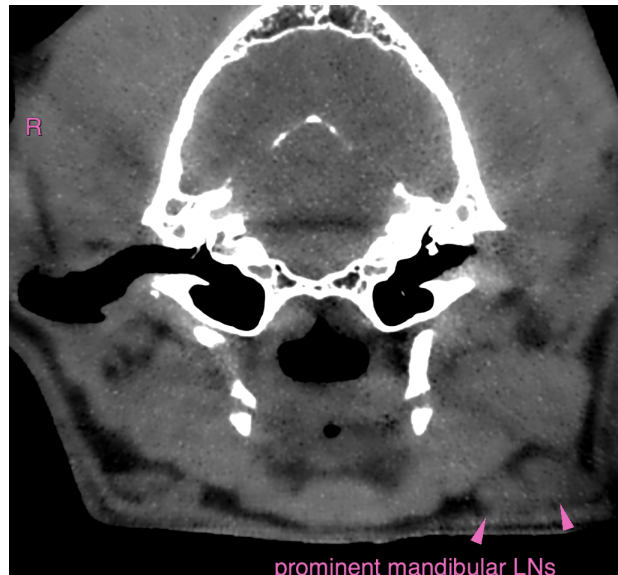
2 Years

INTERPRETED BY

Sebastian Schaub,
DVM Dr. med. vet.
DipECVDI

HOSPITAL NAME

Wilvet Salem



REFERRING VET

Dr. Kristin Peterson

The information and recommendations provided are based on the images presented by the referring veterinarian. No evaluation can be communicated regarding pathology that was not visible in the image/video clips provided.

INVOICE

33097

Thank you for this referral. If the clinical or image interpretation does not parallel your findings or if I can be of any further assistance please contact me.

DATE

11/25/21

Sebastian Schaub, Sebastian Schaub, DVM, Dr. med. vet. DipECVDI
sebast.schaub@gmail.com