



PATIENT

Lola Lechky

PRESENTING CLINICAL SIGNS

The mass was initially noticed 1 month ago. Not noticed by O, unsure of how long it has been there or any changes to it. Golf ball sized deep mass noted on exam by home veterinarian - left lateral to trachea, mobile. fine needle aspirate was performed, as well as an incisional biopsy was performed. Cytology revealed Epithelial neoplasm - most likely thyroid carcinoma.

SPECIES

Canine

COMPUTED TOMOGRAPHY OF THE NECK & THORAX

A pre- and post-contrast CT study of the neck and thorax in a lung and soft tissue reconstruction are provided for review.

BREED

American Bulldog

COMPUTED TOMOGRAPHIC FINDINGS

Level with C2/C3 at the left lateroventral aspect of the trachea, a well-defined mild heterogeneous soft tissue attenuating and heterogeneous contrast enhancing, ovoid shaped mass is seen measuring 3.8 x 3.3 x 5.2 cm in size. Post contrast administration, multiple small tortuous vessels are seen at the cranial and caudal pole of the mass.

SEX

FS

The right thyroid gland is within normal limits for size, shape and attenuation behavior.

The vertebral endplates T9/T10 present moderate spondylosis formation.

AGE

9 Years

The sternal, cranial mediastinal and tracheobronchial lymph nodes are small elongated with a normal short-to-long-axis-ratio is < 0.5, the attenuation and contrast enhancement pattern is uniform and considered within normal limits.

INTERPRETED BY

Sebastian Schaub, DVM
Dr. med. vet. DipECVDI

The cardiovascular structures are within normal limits. Multiple peripheral segments of the pulmonary arteries present mild mineralizations of the wall.

In the caudomedial aspect of the left caudal lung lobe, adjacent to the esophagus, a well-defined, roundish, soft tissue attenuating and mild heterogeneous contrast enhancing mass, measuring 3.1 cm in diameter is appreciated. The bronchial segment extending into the mass is obliterated by the mass effect.

HOSPITAL NAME

Animal Health Partners

Small incidental gas pockets are seen within the esophageal lumen, there is no evidence of abnormal dilation.

COMPUTED TOMOGRAPHIC DIAGNOSIS

REFERRING VET

Dr. Debbie Reynolds

- Left thyroid mass without signs of vascular invasion
- Solitary pulmonary mass medial aspect left caudal lung lobe
- Very mild segmental mineralization of peripheral pulmonary arteries
- Spondylosis deformans

INVOICE

55365

INTERPRETATION OF THE FINDINGS & FURTHER RECOMMENDATIONS

The mass at the left aspect of the trachea is supporting the diagnosis of primary thyroid neoplasia with carcinoma being most common. Complete surgical excision of the mass is considered feasible.

DATE

11-24-22

There is a solitary pulmonary mass in the left caudal lung lobe which can present pulmonary metastatic disease of the thyroid mass or a second entity unrelated to the pulmonary mass such as primary pulmonary neoplasia (e.g. bronchogenic carcinoma) or granuloma. Complete surgical excision of the pulmonary mass is considered feasible as well. I do not see evidence of additional



PATIENT

Lola Lechky

pulmonary nodular lesions.

The mild mineralization of a pulmonary arteries are suggestive for preceding or ongoing lungworm infection such as *Angiostrongylus* or *Dirofilaria*. Testing for potential infection following the guidelines of the "American Heartworm Society" <https://www.heartwormsociety.org> is recommended.

SPECIES

Canine

BREED

American Bulldog

SEX

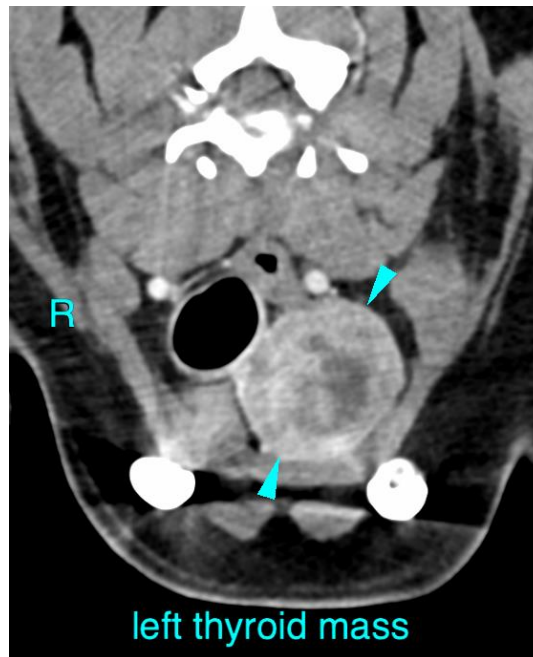
FS

AGE

9 Years

INTERPRETED BY

Sebastian Schaub, DVM
Dr. med. vet. DipECVDI



HOSPITAL NAME

Animal Health
Partners

REFERRING VET

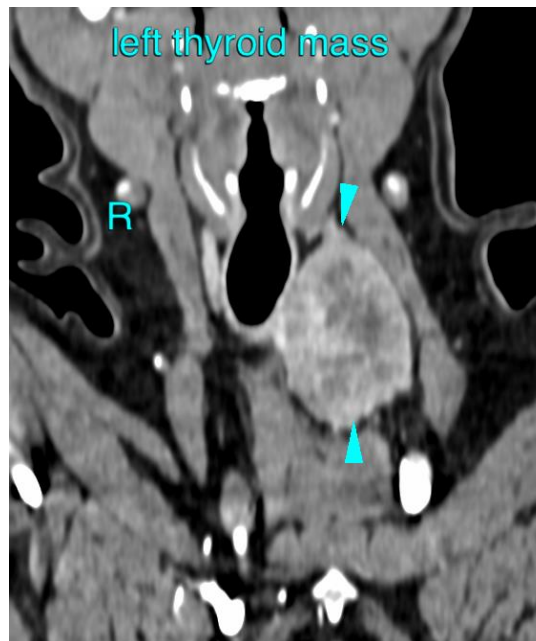Dr. Debbie Reynolds

INVOICE

55365

DATE

11-24-22





PATIENT

Lola Lechky

SPECIES

Canine

BREED

American Bulldog

SEX

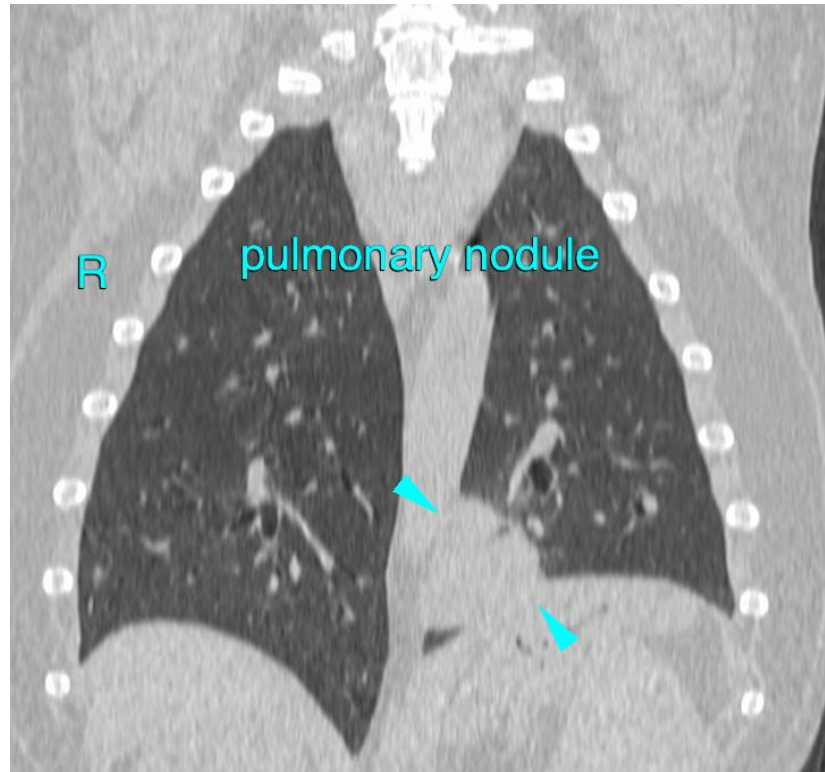
FS

AGE

9 Years

INTERPRETED BY

Sebastian Schaub, DVM
Dr. med. vet. DipECVDI



HOSPITAL NAME

Animal Health
Partners

REFERRING VET

Dr. Debbie Reynolds

INVOICE

55365

DATE

11-24-22

The information and recommendations provided are based on the images presented by the referring veterinarian/sonographer. No evaluation can be communicated regarding pathology that was not visible in the image/video clips provided.

Thank you for this referral. If the clinical or image interpretation does not parallel your findings or if I can be of any further assistance please contact me.

Sebastian Schaub, Sebastian Schaub, DVM, Dr. med. vet. DipECVDI
sebast.schaub@gmail.com