



PATIENT PRESENTING CLINICAL SIGNS

Pony
Ciavarella/Homes
History: right hind leg didn't improve after 10 days of medication
Abnormal PE/Chem/CBC/UA Results: bw unremarkable cranial drawer test positive for the right hind leg

SPECIES RADIOGRAPHIC STUDY OF THE PELVIS AND STIFLE JOINT

Canine Radiographs of the pelvis and right stifle joint in two imaging planes are provided for review.

BREED RADIOGRAPHIC FINDINGS

Mixed The osseous and surrounding soft tissue structures of the pelvis are within normal limits. The coxofemoral joints present smooth osseous margins and thin and congruent joint space, unremarkable.

SEX The volume of the right thigh musculature is moderately decreased.

Spayed Female The periarticular bones of the right stifle joint present mild osteophyte new bone formation. A moderate intracapsular soft tissue swelling of the right stifle joint is visible.

AGE RADIOGRAPHIC DIAGNOSIS

- 3 Years
- Mild degenerative osteoarthritis right stifle joint
 - Moderate articular swelling right stifle joint
 - Disuses atrophy right thigh musculature

INTERPRETED BY

Sebastian Schaub,
DVM Dr. med. vet.
DipECVDI

INTERPRETATION OF THE FINDINGS & FURTHER RECOMMENDATIONS

The radiographic study is consistent with mild chronic degenerative osteoarthritis with concomitant joint effusion of the right stifle joint. The most-likely underlying cause is (partial) rupture of the cranial cruciate ligament with or without meniscal disease.

HOSPITAL NAME

St. Catharine's AH The appreciated positive drawer sign is supporting the diagnosis and surgical intervention appears beneficial.

REFERRING VET

Dr. Masoud

INVOICE

12683

DATE

11/24/21



PATIENT

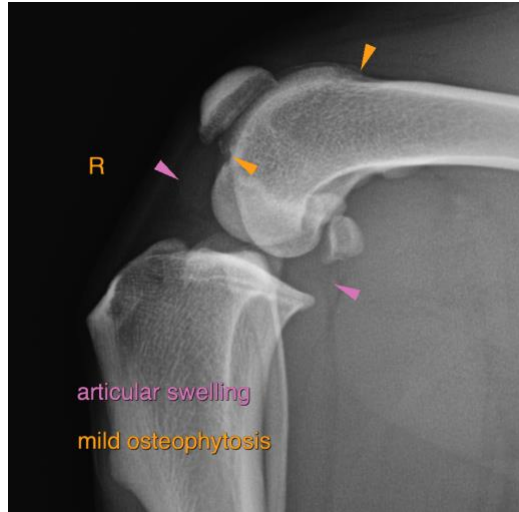
Pony
Ciavarella/Homes

SPECIES

Canine

BREED

Mixed



SEX

Spayed Female

The information and recommendations provided are based on the images presented by the referring veterinarian. No evaluation can be communicated regarding pathology that was not visible in the image/video clips provided.

AGE

3 Years

Thank you for this referral. If the clinical or image interpretation does not parallel your findings or if I can be of any further assistance please contact me.

Sebastian Schaub, Sebastian Schaub, DVM, Dr. med. vet. DipECVDI
sebast.schaub@gmail.com

INTERPRETED BY

Sebastian Schaub,
DVM Dr. med. vet.
DipECVDI

HOSPITAL NAME

St. Catharine's AH

REFERRING VET

Dr. Masoud

INVOICE

12683

DATE

11/24/21