



PATIENT PRESENTING CLINICAL SIGNS

Bunchie Michaels History: Presented for bad breath. On GPE her breath isn't offensive, and her dental health is not bad. O advised she also squeaks at times when breathing, so recommended radiographs of the chest. Otherwise, cat used to vomit a lot before. Now she is on z/d and vomiting has ceased.

SPECIES Abnormal PE/Chem/CBC/UA Results:

Feline RADIOGRAPHIC STUDY OF THE THORAX

Radiographs of the thorax in three imaging planes are provided for review.

BREED RADIOGRAPHIC FINDINGS

DSH Multifocal mild spondylosis formation is seen along the thoracic spine.

SEX The extrathoracic soft tissues present homogeneous without abnormalities.

Neutered Male The heart is of normal size and shape, there is no evidence of cardiac chamber or vascular enlargement. The pulmonary vasculature is within normal limits.

AGE The trachea is normal in diameter and presents the anticipated course. The luminal outline of the trachea is smooth.

8 Years Multifocal mild to moderate peribronchial cuffing is visible.

INTERPRETED BY The lung parenchyma presents the expected architecture and opacity; the intrapulmonary vascular branching is seen up to the third order lung vessels.

Sebastian Schaub, DVM Dr. med. vet. DipECVDI The diaphragm is well delineated with even surface and the expected mild cranial bulging of the diaphragmatic cupola.

HOSPITAL NAME Two small (< 3 mm) mineral opaque calculi are superimposed on the liver, in the region of the gallbladder neck.

Balmy Beach PH

RADIOGRAPHIC DIAGNOSIS

- REFERRING VET**
- Mild bronchial lung pattern
 - Possible cholecystolithiasis versus dystrophic mineralization
 - Spondylosis deformans
- Dr. Singh**

INVOICE INTERPRETATION OF THE FINDINGS & FURTHER RECOMMENDATIONS

12681 The mild bronchial pattern is suggestive for feline lower airway disease ('feline asthma' – no signs for airtrapping in the current case). Allergic causes are considered most likely. The radiographic changes are a potential source for the clinical signs. The use of an asthma inhaler might be considered.

DATE

11/24/21



PATIENT

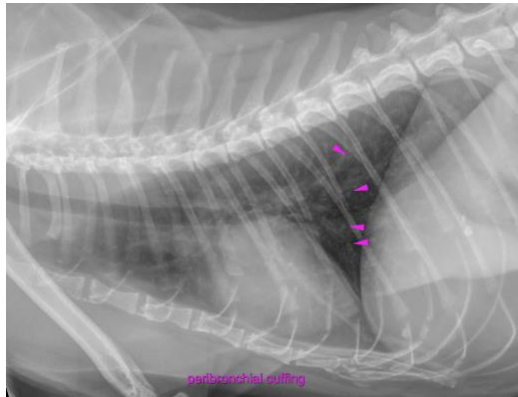
Bunchie Michaels

SPECIES

Feline

BREED

DSH



SEX

Neutered Male

The information and recommendations provided are based on the images presented by the referring veterinarian. No evaluation can be communicated regarding pathology that was not visible in the image/video clips provided.

AGE

8 Years

Thank you for this referral. If the clinical or image interpretation does not parallel your findings or if I can be of any further assistance please contact me.

Sebastian Schaub, Sebastian Schaub, DVM, Dr. med. vet. DipECVDI
sebast.schaub@gmail.com

INTERPRETED BY

Sebastian Schaub,
DVM Dr. med. vet.
DipECVDI

HOSPITAL NAME

Balmy Beach PH

REFERRING VET

Dr. Singh

INVOICE

12681

DATE

11/24/21