



PATIENT PRESENTING CLINICAL SIGNS

Hallie Smith Presented Nov 8, 2022 for evaluation of mobility problems, worst on RHL. Started to be wobbly in the pelvic limbs about 2 weeks prior to her ventral slot surgery - had C6-7 ventral slot at different hospital in Sept 2022 and was non ambulatory after surgery. O feels she improved back to baseline by the time of suture removal but has not overall improved and is the same as pre-op. PE: Significant pain elicited on palpation of the distal tibia bilaterally, worse on the right. Hx bilat TPLOs in 2018

SPECIES

Canine

BREED

Bernese Mountain Dog

COMPUTED TOMOGRAPHY OF THE THORAX, ABDOMEN AND HIND LIMBS

A plain CT study of the thorax, abdomen and the hind limbs in a bone, lung and soft tissue reconstruction is provided for review.

COMPUTED TOMOGRAPHIC FINDINGS

Thorax

SEX

FS

The intervertebral disc space C6/C7 is collapsed. Mild spondylosis formation is seen along the caudal thoracic spine. The periarticular bones of both shoulder joints present mild osteophyte new bone formation. A spindle shaped lipoma is seen in the cranial aspect of the right axillary region.

AGE

10 Years

The sternal, cranial mediastinal and tracheobronchial lymph nodes are small elongated with a normal short-to-long-axis-ratio is < 0.5, the attenuation pattern is uniform and considered within normal limits.

INTERPRETED BY

Sebastian Schaub, DVM
Dr. med. vet. DipECVDI

The cardiovascular structures including the pulmonary vasculature are within normal limits.

The bronchial tree presents with regular branching and tapers uniformly towards the periphery as expected, the bronchial walls are thin and smooth. The bronchus-to-artery ratio is within normal limits.

HOSPITAL NAME

Animal Health Partners

The lung parenchyma presents the expected architecture and attenuation behavior, but zones of dystelectasis of the ventral dependent aspects of the lung.

Small incidental gas pockets are seen within the esophageal lumen, there is no evidence of abnormal dilation.

Abdomen

REFERRING VET

Dr. Jeffery Biskup

The serosal fat presents normal attenuation behavior. There is no evidence of peritoneal effusion or peritonitis.

Both kidneys present within normal limits for size, shape and organ architecture. After contrast administration a bilaterally symmetric and uniform nephro- and pyelogram is noted.

INVOICE

55347

The adrenal glands are within normal limits for size, shape and organ architecture.

Both liver and spleen present with normal shape, even surface, uniformly attenuating parenchyma.

DATE

11-23-22

The pancreas is evenly contoured, the pancreatic parenchyma is homogeneous.

The position, delineation, wall and content of the gastrointestinal tract are considered within normal limits throughout.



PATIENT The right medial iliac lymph node is prominent.

Hallie Smith The intervertebral discs L6/L7 and L7/S1 are mildly protruding into the vertebral canal, distorting the ventral epidural space at the same level.

SPECIES Hind limbs

Canine At the caudal aspect of the greater trochanter of the right femur, well-defined fat attenuating mass is seen, measuring 2.6 x 2.7 x 5.1 cm in size. The right sciatic nerve at the same level is in contact with the fat attenuating mass and mildly deviated cranially.

BREED The periarticular bones of both stifle joints present mild osteophyte new bone formation. A TPLO implant is seen along the medioproximal aspect of the tibia bilaterally.

Bernese Mountain Dog In the subcutaneous tissue at the lateroproximal aspect of the right stifle joint, a well-defined, ovoid shaped lipoma is seen, measuring 3.4 cm in diameter.

SEX The distal metaphysis of the right tibia presents an ill-defined zone with permeative osteolytic lesions and multifocal endosteal scalloping of the cortex is seen at the same level. Post contrast administration, the medullary cavity of the right distal metaphysis of the tibia presents a heterogeneous contrast enhancement pattern.

FS

The periarticular bones of both tarsal joints present mild osteophyte new bone formation.

AGE **COMPUTED TOMOGRAPHIC DIAGNOSIS**

- 10 Years
- Monostotic aggressive osteolytic lesion distal right tibia
 - Lymphadenopathy right medial iliac lymph node
 - History of management of cranial cruciate ligament pathology bilaterally by TPLO
 - Mild degenerative osteoarthritis stifle & tarsal joints bilaterally
 - Mild degenerative osteoarthritis shoulder joints bilaterally
 - Lipoma right axillary region
 - Chronic discopathy C6/C7
 - Spondylosis deformans
 - No evidence of pulmonary metastatic disease

INTERPRETED BY

Sebastian Schaub, DVM
Dr. med. vet. DipECVDI

HOSPITAL NAME

Animal Health
Partners

REFERRING VET

Dr. Jeffery Biskup

INTERPRETATION OF THE FINDINGS & FURTHER RECOMMENDATIONS

The aggressive bone lesion of the right distal tibia is highly suggestive for primary osseous neoplasia – such as osteosarcoma, chondrosarcoma, hemangiosarcoma, fibrosarcoma, round cell tumor. Osteomyelitis is a consideration as well, but the odds are low. The prominent tributary right medial iliac lymph node is equivocal for reactive hyperplasia or metastatic disease. Recommend FNA sampling ± bone biopsy of the distal right tibia and the ipsilateral medial iliac lymph node for further definition.

INVOICE

55347

DATE

11-23-22



PATIENT

Hallie Smith

SPECIES

Canine

BREED

Bernese Mountain
Dog

SEX

FS

AGE

10 Years

INTERPRETED BY

Sebastian Schaub, DVM
Dr. med. vet. DipECVDI

HOSPITAL NAME

Animal Health
Partners

REFERRING VET

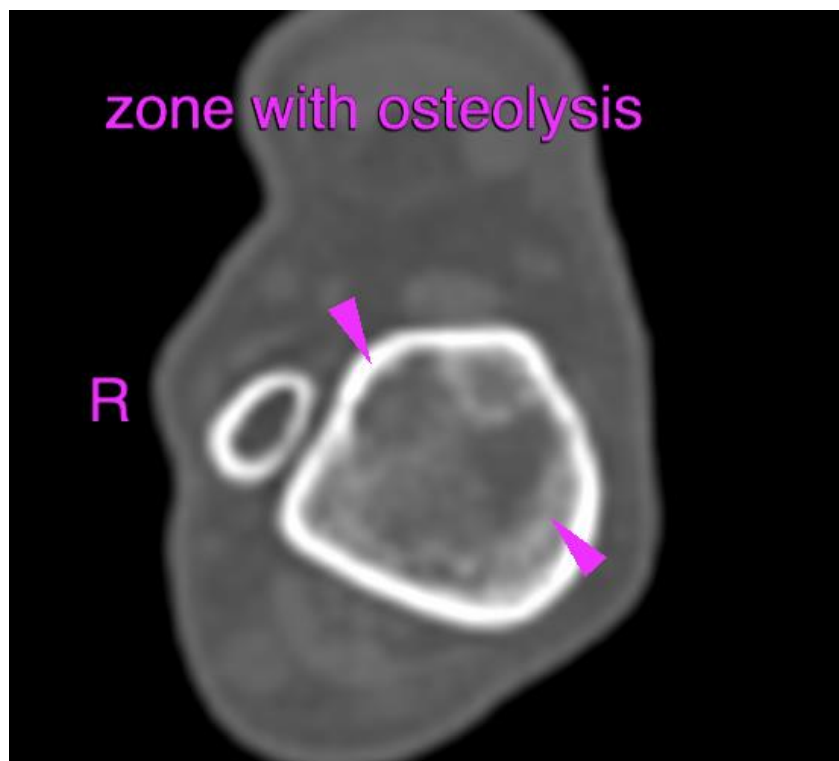
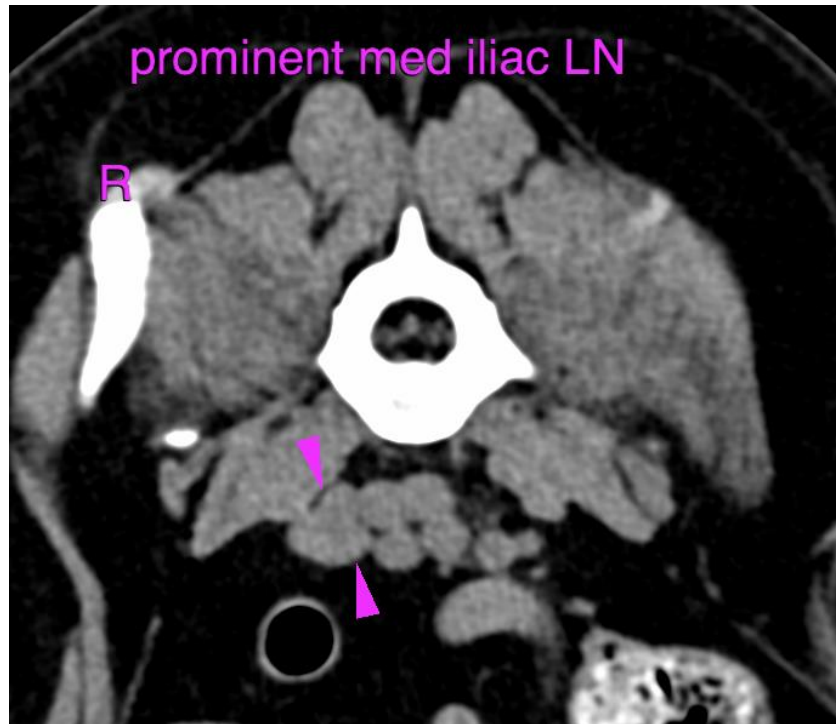
Dr. Jeffery Biskup

INVOICE

55347

DATE

11-23-22





PATIENT

Hallie Smith

SPECIES

Canine

BREED

Bernese Mountain
Dog

SEX

FS

AGE

10 Years

INTERPRETED BY

Sebastian Schaub, DVM
Dr. med. vet. DipECVDI

HOSPITAL NAME

Animal Health
Partners

REFERRING VET

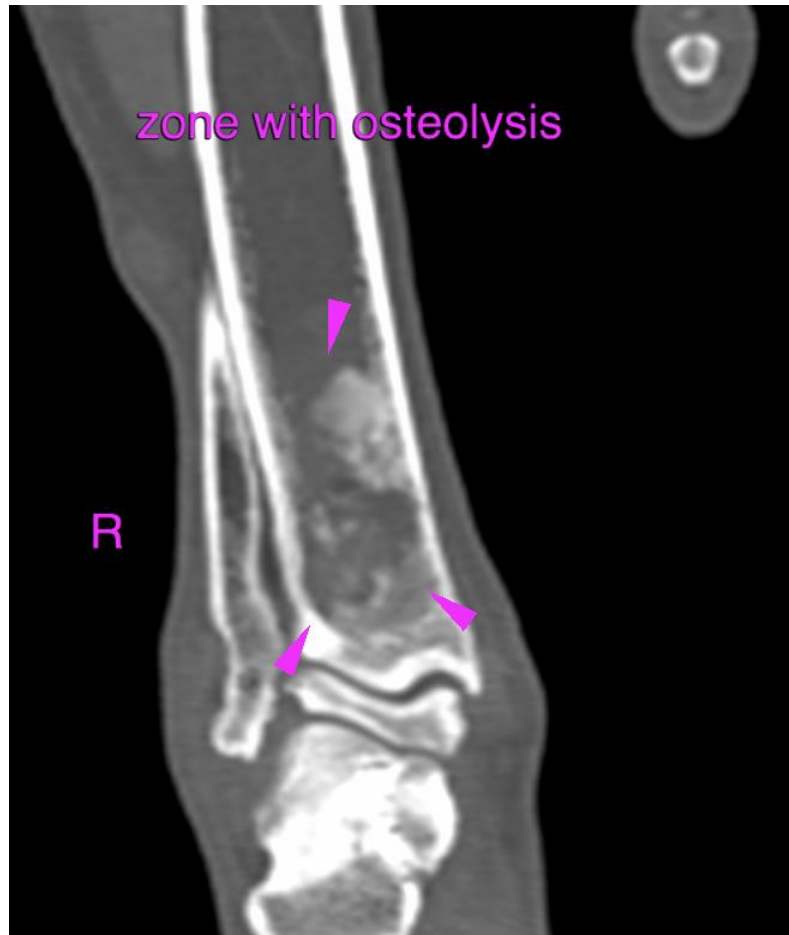
Dr. Jeffery Biskup

INVOICE

55347

DATE

11-23-22



The information and recommendations provided are based on the images presented by the referring veterinarian/sonographer. No evaluation can be communicated regarding pathology that was not visible in the image/video clips provided.

Thank you for this referral. If the clinical or image interpretation does not parallel your findings or if I can be of any further assistance please contact me.

Sebastian Schaub, Sebastian Schaub, DVM, Dr. med. vet. DipECVDI
sebast.schaub@gmail.com