

**PATIENT**

Copper Ciomber

SPECIES

Canine

BREED

Vizsla

SEX

FS

AGE

10 Years, 11 Months

INTERPRETED BYSebastian Schaub, DVM
Dr. med. vet. DipECVDI**HOSPITAL NAME**Elizabeth Animal
Hospital**REFERRING VET**

Kim Allyn, DVM

INVOICE

55346

DATE

11-23-22

PRESENTING CLINICAL SIGNS

Copper has been limping on her right front on and off for the past 4 weeks and occasionally before that as well (some history of it in 2019 and so on) Recently it has been bothering her more where she lifts her leg up when she is standing there or laying there.

Abnormal PE/Chem/CBC/UA Results: Very sore on top of the right scapula.

RADIOGRAPHIC STUDY OF THE SHOULDER JOINTS

Radiographs of both shoulder joints in two orthogonal imaging planes are provided for review.

RADIOGRAPHIC FINDINGS

The scapula bilaterally has a homogeneous trabecular pattern. The proximal margin of the scapula bilaterally is physiologically mildly irregular

Both shoulder joints present smooth osseous margins and no abnormalities of the surrounding soft tissue structures are appreciated.

RADIOGRAPHIC DIAGNOSIS

- Normal shoulder joints

INTERPRETATION OF THE FINDINGS & FURTHER RECOMMENDATIONS

The radiographic study of the shoulder joints presents without pathologies. The mild irregularity of the proximal margin of the scapula is considered normal. If clinical findings are suggestive for pathology of the scapula – e.g. pain during palpation – radiographs of the scapula dorsal to the vertebral column can be performed to avoid superimposition with the thoracic structures potentially effacing more subtle lesions: patient is placed in lateral recumbency with the affected leg on the cassette and pushed dorsally to displace the scapula dorsal to the vertebral column – the scapula will flex caudally paralleling the thoracic spine.

Rule out pain originating from the brachial plexus or the elbow joints as source for the described clinical signs as well.



PATIENT

Copper Ciomber

SPECIES

Canine

BREED

Vizsla

SEX

FS

AGE

10 Years, 11 Months

INTERPRETED BY

Sebastian Schaub, DVM
Dr. med. vet. DipECVDI

HOSPITAL NAME

Elizabeth Animal
Hospital

REFERRING VET

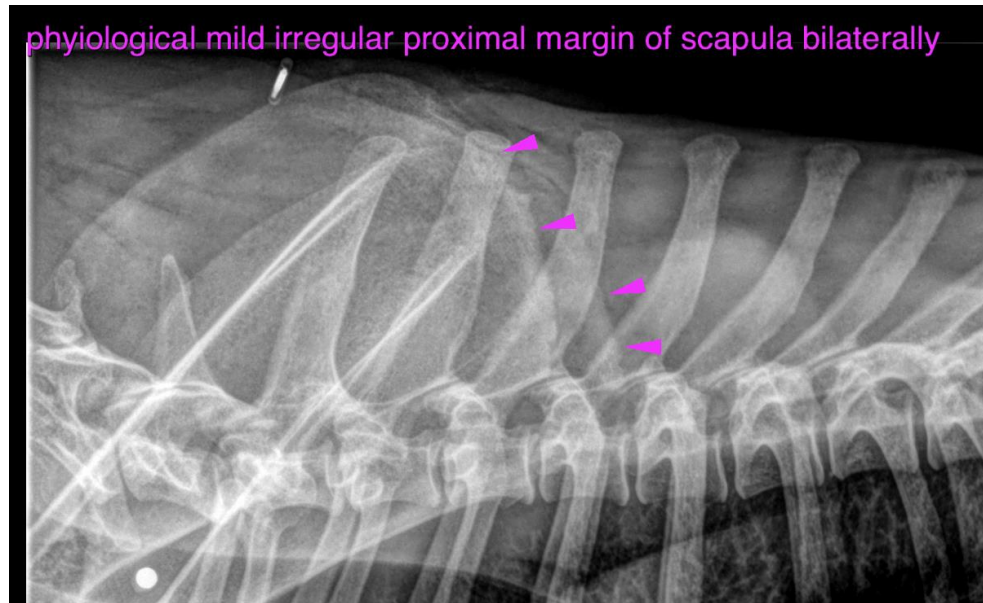
Kim Allyn, DVM

INVOICE

55346

DATE

11-23-22



The information and recommendations provided are based on the images presented by the referring veterinarian/sonographer. No evaluation can be communicated regarding pathology that was not visible in the image/video clips provided.

Thank you for this referral. If the clinical or image interpretation does not parallel your findings or if I can be of any further assistance please contact me.

Sebastian Schaub, Sebastian Schaub, DVM, Dr. med. vet. DipECVDI
sebast.schaub@gmail.com