



PATIENT PRESENTING CLINICAL SIGNS

Ben Nunez Cushing's, lethargic, with loss of skull muscle and face, electrolyte imbalance, loss of appetite, respiratory congestion, and nasal discharge pending respiratory PCR.
Abnormal PE/Chem/CBC/UA Results: Fractious despite being recumbent, generalized dermatitis, calcinosis cutis. Progressive loss of weight, lethargy, loss of face and skull muscle, nose discharge, partial respiratory obstruction.

SPECIES

Canine

COMPUTED TOMOGRAPHY OF THE SKULL, THORAX AND ABDOMEN

BREED

A high resolution pre- and post-contrast CT study of the skull and abdomen and a post-contrast CT study of the thorax are provided for review.

American Bulldog

COMPUTED TOMOGRAPHIC FINDINGS

Generalized mineralization along the muscular fascial planes of the masticatory muscles, axial musculature and the subcutaneous tissues is seen.

SEX

Neutered Male

Skull

The pictured parts of the dentition are complete and unremarkable in all jaw quadrants.

AGE

6 Years

The nasal cavity presents the expected aerated spaces between thin & even conchae and turbinates with smooth mucosal lining. The soft palate is elongated and thickened.

Both temporomandibular joints present congruent joint spaces with even subchondral bone surfaces and are considered within normal limits.

INTERPRETED BY

Sebastian Schaub, DVM
 Dr. med. vet. DipECVDI

The right tympanic bulla is filled with soft tissue attenuating material. The external ear canals present a prominent wall with moderate shell-like mineralization.

Originating from the pituitary fossa, a well-defined, conical shaped, mild contrast enhancing mass is appreciated, measuring 2.2 x 1.6 x 1.3 cm in size; protruding into the cranial fossa.

HOSPITAL NAME

Mobile Pet Imaging

The submandibular and medial retropharyngeal lymph nodes are small and elongated with a normal short-to-long-axis-ratio is < 0.5, the attenuation and contrast enhancement pattern is uniform.

Thorax

Multifocal spondylosis formation is seen along the thoracic spine.

REFERRING VET

Meaux

The sternal, cranial mediastinal and tracheobronchial lymph nodes are small elongated with a normal short-to-long-axis-ratio is < 0.5, the attenuation and contrast enhancement pattern is uniform and considered within normal limits.

INVOICE

55343

The cardiovascular structures including the pulmonary vasculature are within normal limits.

Generalized mild, smooth thickening of the bronchial walls is appreciated.

The lung parenchyma presents the expected architecture and attenuation behavior with randomly distributed interspersed punctuate mineralization.

DATE

11-23-22

Small incidental gas pockets are seen within the esophageal lumen, there is no evidence of abnormal dilation.

Abdomen



PATIENT The serosal fat presents normal attenuation behavior. There is no evidence of peritoneal effusion or peritonitis.

Ben Nunez Both kidneys present within normal limits for size, shape and organ architecture. After contrast administration a bilaterally symmetric and uniform nephro- and pyelogram is noted.

SPECIES The adrenal glands are within normal limits for shape and organ architecture. Both adrenal glands present a increased maximum cross-sectional diameter, measuring up to 14 mm.

Canine Both liver and spleen present with normal shape, even surface, uniformly attenuating parenchyma and homogeneous contrast enhancement, unremarkable.

BREED In the hilar region of the liver, a filling defect is seen in the portal vein extending into the right lateral branch and left intrahepatic branch of the portal vein. The splenic vein and its branches in the hilar region present with intraluminal filling defects and multiple segments of intraluminal mineralization.

American Bulldog

SEX The pancreas is evenly contoured, the pancreatic parenchyma is homogeneous and presents uniform contrast enhancement.

Neutered Male The position, delineation, wall and content of the gastrointestinal tract are considered within normal limits throughout.

AGE The lumbosacral intervertebral disc is protruding into the vertebral canal, occupying approximately 50% of the cross-sectional area of the vertebral canal at the same level. The vertebral endplates of the lumbosacral junction present moderate spondylosis formation. Both coxofemoral joints present moderate osteophyte new bone formation. The acetabular groove bilaterally is shallow and the center of the femoral heads is lateral to the dorsal acetabular rim.

6 Years

INTERPRETED BY COMPUTED TOMOGRAPHIC DIAGNOSIS

Sebastian Schaub, DVM
Dr. med. vet. DipECVDI

- Pituitary mass
- Bilateral adrenomegaly
- Portal vein and splenic vein thrombosis (chronic with dystrophic mineralization)
- Advanced calcinosis cutis
- Thickened & elongated soft palate
- Degenerative lumbosacral stenosis with potential dynamic compression of the cauda equina fibers
- Right sided otitis media

HOSPITAL NAME

Mobile Pet Imaging

REFERRING VET

Meaux

INTERPRETATION OF THE FINDINGS & FURTHER RECOMMENDATIONS

The findings are consistent with pituitary dependent hyperadrenocorticism and secondary adrenal hyperplasia, calcinosis cutis and portal & splenic vein thrombosis due to secondary hypercoagulable state.

INVOICE

55343

DATE

11-23-22



PATIENT

Ben Nunez

SPECIES

Canine

BREED

American Bulldog

SEX

Neutered Male

AGE

6 Years

INTERPRETED BY

Sebastian Schaub, DVM
Dr. med. vet. DipECVDI

HOSPITAL NAME

Mobile Pet Imaging

REFERRING VET

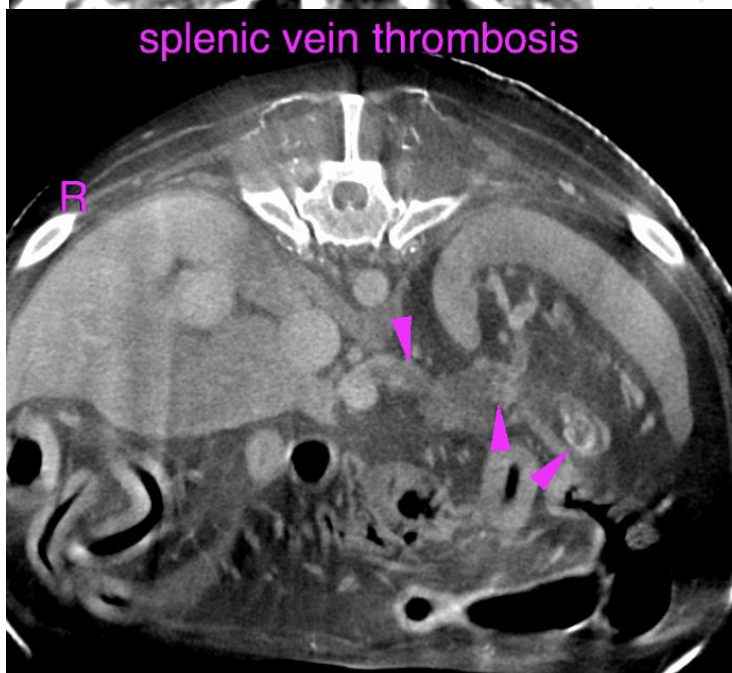
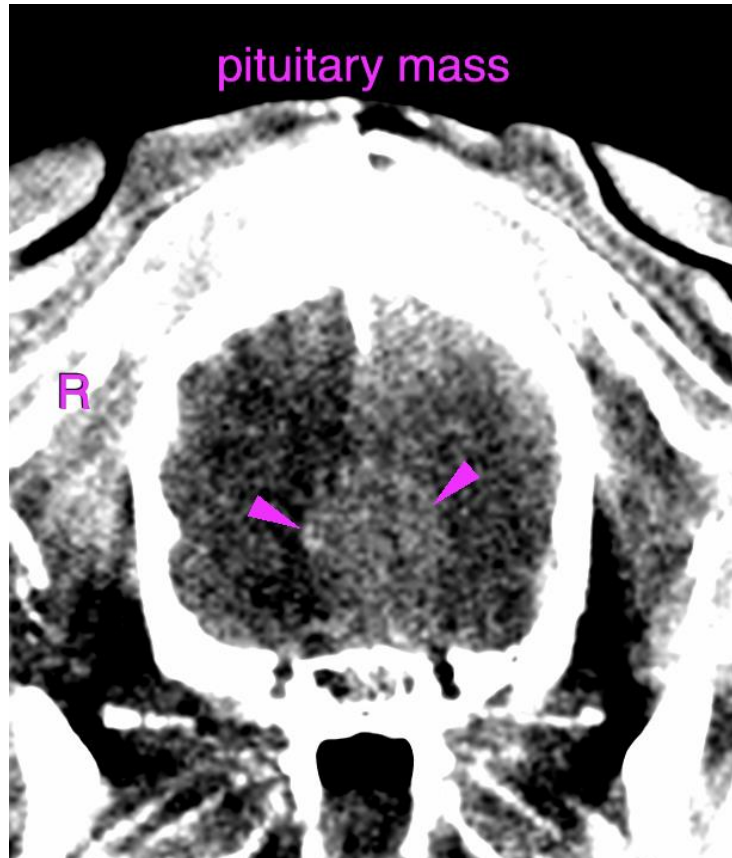
Meaux

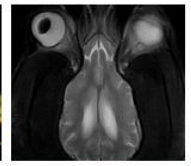
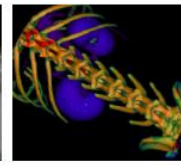
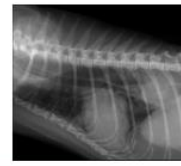
INVOICE

55343

DATE

11-23-22





PATIENT

Ben Nunez

SPECIES

Canine

BREED

American Bulldog

SEX

Neutered Male

AGE

6 Years

INTERPRETED BY

Sebastian Schaub, DVM
Dr. med. vet. DipECVDI

HOSPITAL NAME

Mobile Pet Imaging

REFERRING VET

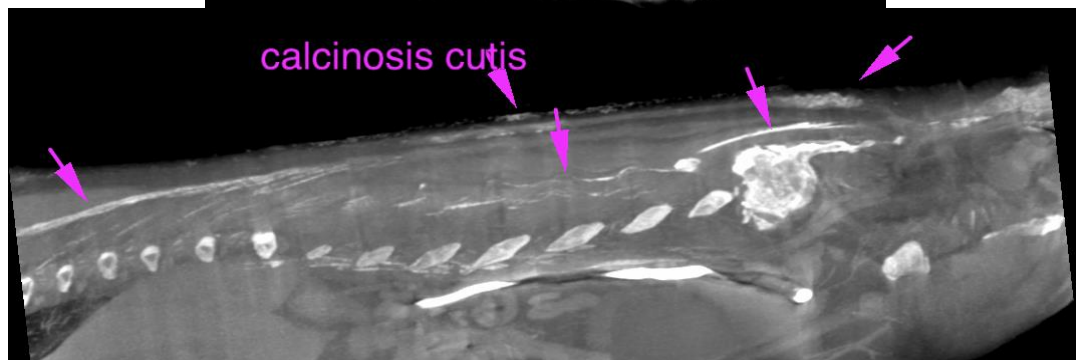
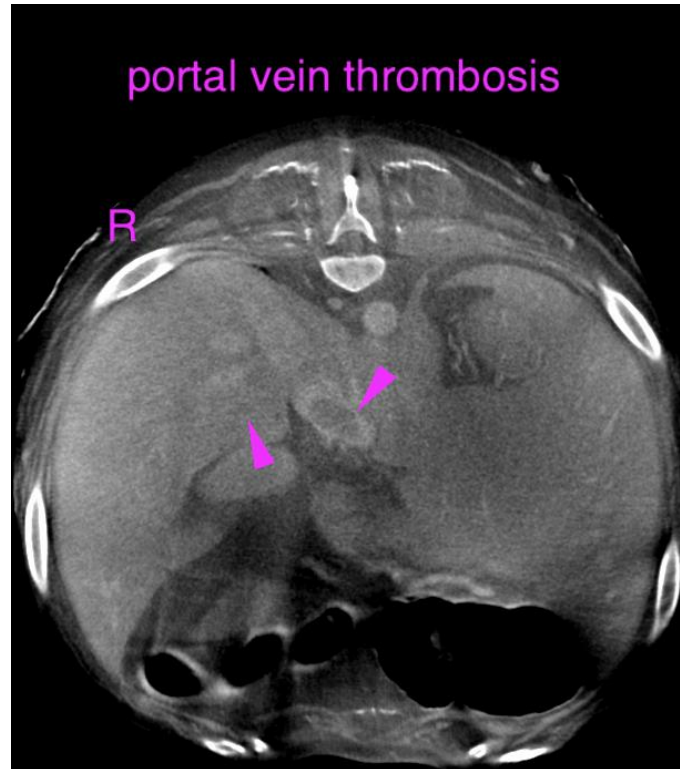
Meaux

INVOICE

55343

DATE

11-23-22



The information and recommendations provided are based on the images presented by the referring veterinarian/sonographer. No evaluation can be communicated regarding pathology that was not visible in the image/video clips provided.

Thank you for this referral. If the clinical or image interpretation does not parallel your findings or if I can be of any further assistance please contact me.

Sebastian Schaub, Sebastian Schaub, DVM, Dr. med. vet. DipECVDI
sebast.schaub@gmail.com