


PATIENT PRESENTING CLINICAL SIGNS

Cookie Lombardo increased wheezing

RADIOGRAPHIC STUDY OF THE THORAX
SPECIES

Radiographs of the thorax in two orthogonal imaging planes are provided for review.

Feline

RADIOGRAPHIC FINDINGS
BREED

Multifocal mild spondylosis formation is seen along the thoracic spine.

Tortoiseshell

The extrathoracic soft tissues present homogeneous without abnormalities.

SEX

The heart is of normal size and shape, there is no evidence of cardiac chamber or vascular enlargement. The pulmonary vasculature is within normal limits.

Spayed Female

The trachea is normal in diameter and presents the anticipated course. The luminal outline of the trachea is smooth.

AGE

Multifocal mild to moderate peribronchial cuffing is present. There is a mild increased distance between the cardiac silhouette and the diaphragm. The diaphragm presents a mild flattened course.

11 Years

The lung parenchyma presents the expected architecture and opacity; the intrapulmonary vascular branching is seen up to the third order lung vessels.

INTERPRETED BY

Sebastian Schaub,
 DVM Dr. med. vet.
 DipECVDI

The diaphragm is well delineated with even surface and the expected mild cranial bulging of the diaphragmatic cupola.

RADIOGRAPHIC DIAGNOSIS

- Bronchial lung pattern with mild air-trapping
- Spondylosis deformans thoracic spine

HOSPITAL NAME

Rockaway AH

INTERPRETATION OF THE FINDINGS & FURTHER RECOMMENDATIONS

The radiographic study is compatible with 'feline asthma'. Treatment by the use of an asthma inhaler appears beneficial.

REFERRING VET

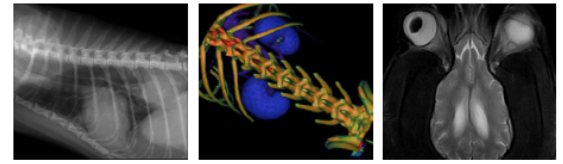
Dr. Maniar

INVOICE

30078

DATE

11/23/21



PATIENT

Cookie Lombardo

SPECIES

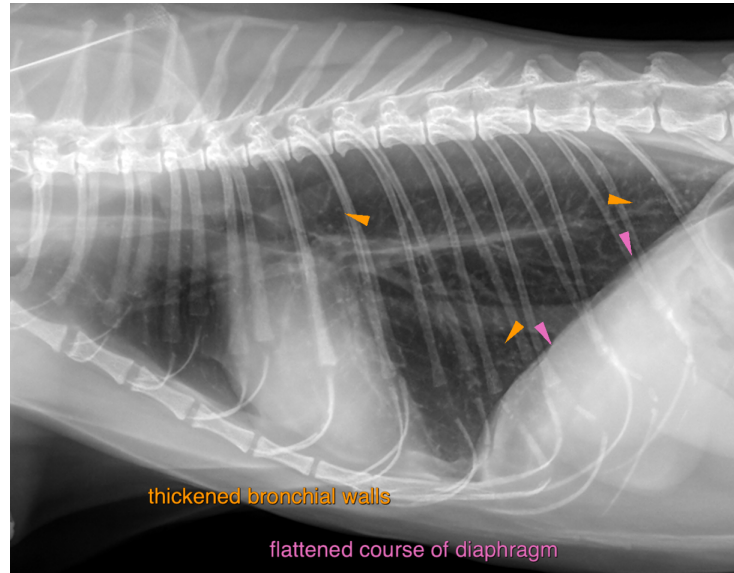
Feline

BREED

Tortoiseshell

SEX

Spayed Female



AGE

11 Years

The information and recommendations provided are based on the images presented by the referring veterinarian. No evaluation can be communicated regarding pathology that was not visible in the image/video clips provided.

INTERPRETED BY

Sebastian Schaub,
DVM Dr. med. vet.
DipECVDI

Thank you for this referral. If the clinical or image interpretation does not parallel your findings or if I can be of any further assistance please contact me.

Sebastian Schaub, Sebastian Schaub, DVM, Dr. med. vet. DipECVDI
sebast.schaub@gmail.com

HOSPITAL NAME

Rockaway AH

REFERRING VET

Dr. Maniar

INVOICE

30078

DATE

11/23/21