



**PATIENT PRESENTING CLINICAL SIGNS**

**PATIENT** Odin Price  
 Adopted in June 2022, is sore on HL's & FL's, worsening recently, is stiff, lucency on LFL distal radius at mid medullary cavity. Highly suspect LFL radial OSA. Bilateral Stifle OA. Suspect LS stenosis - very poor tail jack - about 40% normal.

**SPECIES** Abnormal PE/Chem/CBC/UA Results: On gabapentin & metacam started today, firm warm swelling on left carpus.

Canine

**RADIOGRAPHIC STUDY OF THE LEFT CARPUS**

Radiographs of the left carpal joint in a mediolateral and dorsopalmar projection are provided for review.

**BREED**

Great Dane

**RADIOGRAPHIC FINDINGS**

The distal metaphysis of the radius including the distal diaphysis of the radius present an ill-defined zone with permeative osteolysis and accompanying immature periosteal new bone formation. Advanced lysis of the caudal cortex of the distal radius is seen. A mild circumferential soft tissue swelling is seen along the distal segment of the radius.

**SEX**

Neutered Male

The osseous of the carpal joint are within normal limits.

**AGE**

6

**RADIOGRAPHIC DIAGNOSIS**

- Monostotic aggressive osteolytic lesion distal left radius

**INTERPRETED BY**

Sebastian Schaub, DVM  
 Dr. med. vet. DipECVDI

**INTERPRETATION OF THE FINDINGS & FURTHER RECOMMENDATIONS**

The radiographic study is consistent with primary osseous neoplasia originating from the left distal radius and osteosarcoma is most common. FNA sampling can be used to confirm the diagnosis.

**HOSPITAL NAME**

River Valley  
 Veterinary Wellness  
 Clinic

Consider complementing full tumor staging by thoracic radiographs.

**REFERRING VET**

Jennifer Stelfox

**INVOICE**

55331

**DATE**

11-22-22



**PATIENT**

Odin Price

**SPECIES**

Canine

**BREED**

Great Dane

**SEX**

Neutered Male

**AGE**

6

**INTERPRETED BY**

Sebastian Schaub, DVM  
Dr. med. vet. DipECVDI

**HOSPITAL NAME**

River Valley  
Veterinary Wellness  
Clinic

**REFERRING VET**

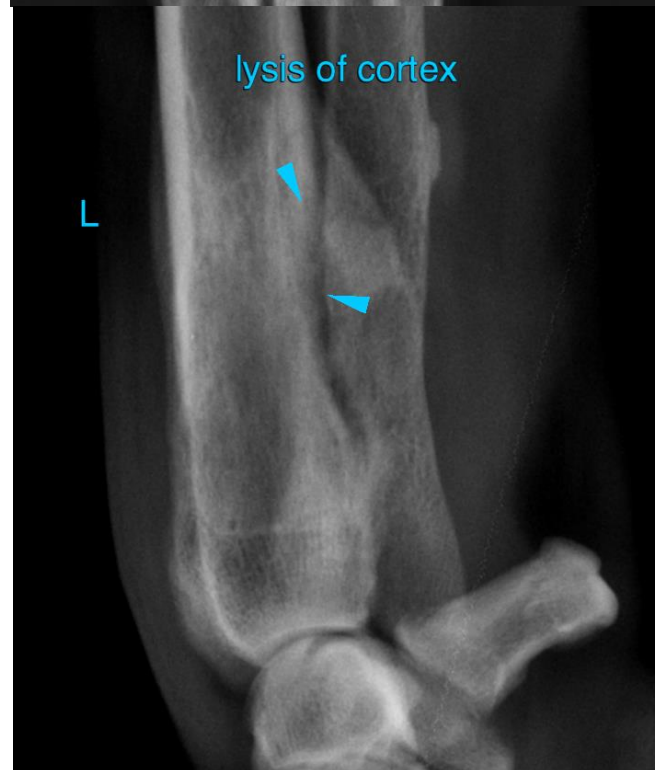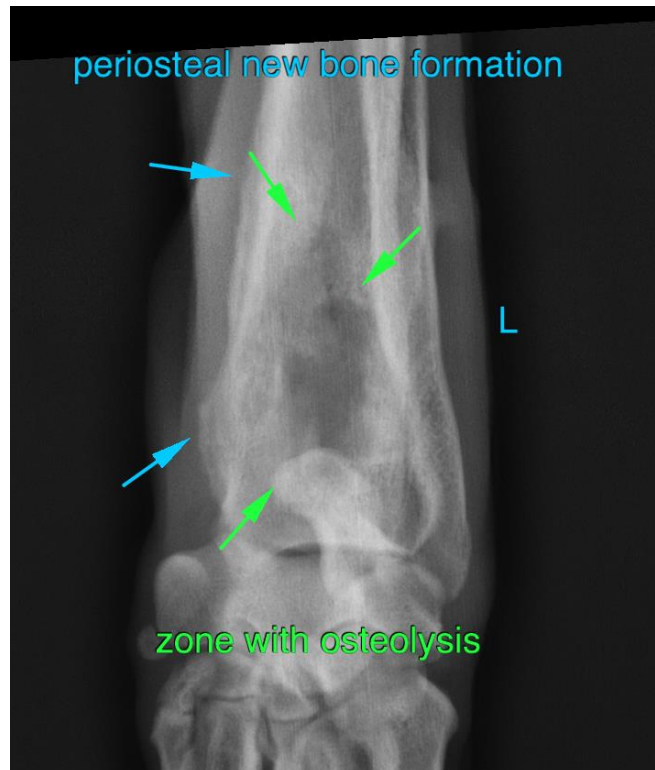
Jennifer Stelfox

**INVOICE**

55331

**DATE**

11-22-22





**PATIENT**

Odin Price

**SPECIES**

Canine

The information and recommendations provided are based on the images presented by the referring veterinarian/sonographer. No evaluation can be communicated regarding pathology that was not visible in the image/video clips provided.

**BREED**

Great Dane

Thank you for this referral. If the clinical or image interpretation does not parallel your findings or if I can be of any further assistance please contact me.

**SEX**

Neutered Male

**Sebastian Schaub**, Sebastian Schaub, DVM, Dr. med. vet. DipECVDI  
sebast.schaub@gmail.com

**AGE**

6

**INTERPRETED BY**

Sebastian Schaub, DVM  
Dr. med. vet. DipECVDI

**HOSPITAL NAME**

River Valley  
Veterinary Wellness  
Clinic

**REFERRING VET**

Jennifer Stelfox

**INVOICE**

55331

**DATE**

11-22-22