



**PATIENT PRESENTING CLINICAL SIGNS**

**PATIENT** Midnight Holley  
**SPECIES** Mass on face first noted in May 2022. Has been treated at other clinic with various antibiotics- no improvement noted. It has continued to grow and is now causing significant facial deformation and is bother the pet. Biopsy was taken after the CT and thick mucoid material was cultured from the biopsy site.

**Feline**

Abnormal PE/Chem/CBC/UA Results: Mild leukocytosis, mature neutrophilia

**COMPUTED TOMOGRAPHY OF THE SKULL**

A high resolution pre- and post-contrast CT study of the skull is provided for review.

**BREED**

**DSH**

**COMPUTED TOMOGRAPHIC FINDINGS**

Triadan 206 is absent. Triadan 207 & 407 present advanced resorptive lesions of the crown. Triadan 304 presents a moderate widened periodontal space.

**SEX**

**MN**

The caudodorsal aspect of the right nasal cavity is obliterated by soft tissue attenuating and heterogeneous contrast enhancing expansile soft tissue material. The caudal segment of the right maxillary bone and right nasal bone present aggressive osteolysis and outward deviation of the osseous lining, the nasal soft tissue mass is protruding into the subcutaneous tissue at the rostral aspect of the right orbit. Osteolysis of the right lateral aspect of the cribriform plate is appreciated and mild contrast enhancing material is bulging into the right rostral cranial fossa.

**AGE**

12 Years, 10 Months

Both temporomandibular joints present congruent joint spaces with even subchondral bone surfaces and are considered within normal limits.

**INTERPRETED BY**

Sebastian Schaub, DVM  
 Dr. med. vet. DipECVDI

Both tympanic bullae are aerated, the mucosal lining is not seen, the bony wall is smooth and thin. The external ear canals are within normal limits.

**HOSPITAL NAME**

Wilson Veterinary Hospital

The brain presents no deviation from normal anatomy and symmetry. The brain parenchyma is homogeneous and within normal limits for attenuation and distribution of contrast enhancement. The ventricular system is non-dilated and symmetric.

The submandibular and medial retropharyngeal lymph nodes are small and elongated with a normal short-to-long-axis-ratio is < 0.5, the attenuation and contrast enhancement pattern is uniform.

**REFERRING VET**

Dr. Shanti Subramanian

**COMPUTED TOMOGRAPHIC DIAGNOSIS**

- Expansile nasal soft tissue mass originating from the right caudodorsal aspect of the nasal cavity with polyostotic aggressive osteolytic lesions of the associated osseous structures and perforation of the cranial fossa
- Advanced dental resorptive lesions 307&407
- Periodontal disease 304
- Absent triadan 206

**INVOICE**

55328

**INTERPRETATION OF THE FINDINGS & FURTHER RECOMMENDATIONS**

The expansile nasal mass is compatible with primary nasal neoplasia with evidence of perforation of the cranial fossa. Differentials include adenocarcinoma, squamous cell carcinoma, transitional cell carcinoma, lymphosarcoma, other. Biopsy has already been performed for further definition.

**DATE**

11-22-22

Consider full tumor staging.



**PATIENT**

Midnight Holley

**SPECIES**

Feline

**BREED**

DSH

**SEX**

MN

**AGE**

12 Years, 10 Months

**INTERPRETED BY**

Sebastian Schaub, DVM  
Dr. med. vet. DipECVDI

**HOSPITAL NAME**

Wilson Veterinary  
Hospital

**REFERRING VET**

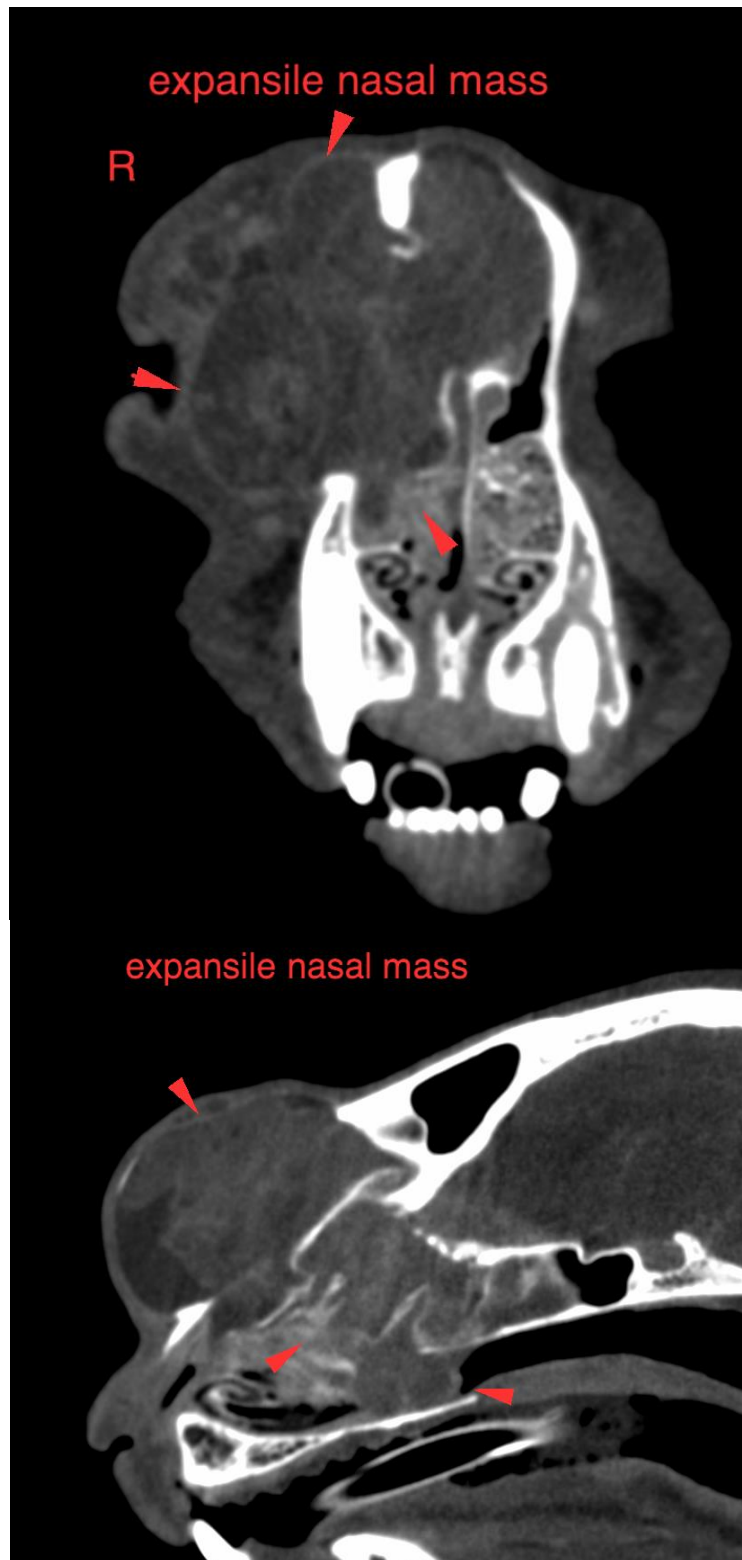
Dr. Shanti  
Subramanian

**INVOICE**

55328

**DATE**

11-22-22





**PATIENT**

Midnight Holley

**SPECIES**

Feline

**BREED**

DSH

**SEX**

MN

**AGE**

12 Years, 10 Months

**INTERPRETED BY**

Sebastian Schaub, DVM  
Dr. med. vet. DipECVDI

**HOSPITAL NAME**

Wilson Veterinary  
Hospital

**REFERRING VET**

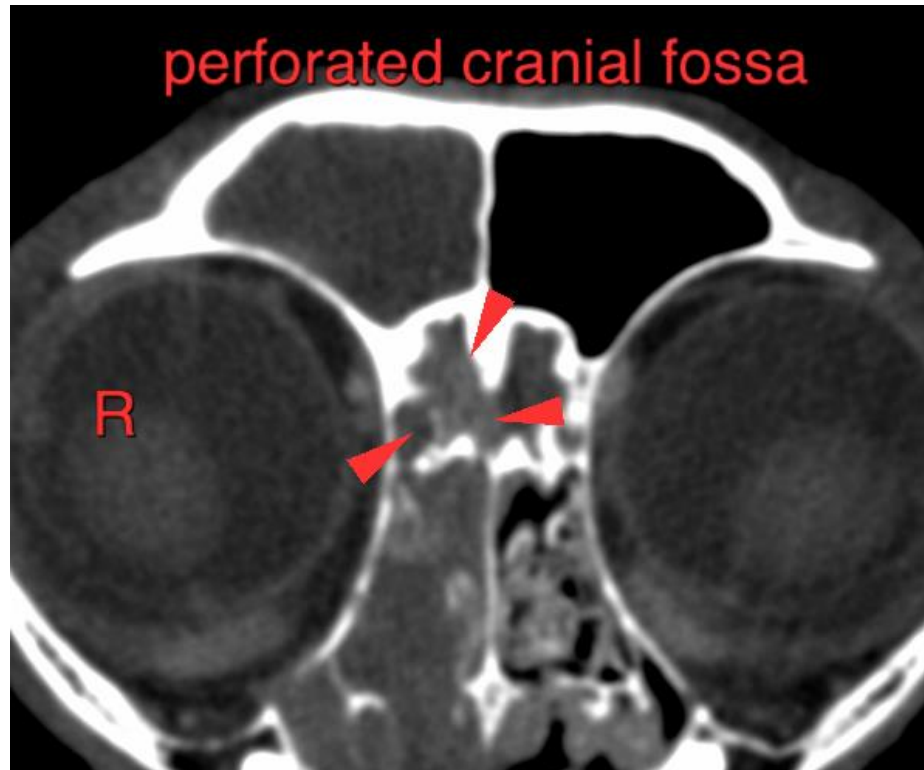
Dr. Shanti  
Subramanian

**INVOICE**

55328

**DATE**

11-22-22



The information and recommendations provided are based on the images presented by the referring veterinarian/sonographer. No evaluation can be communicated regarding pathology that was not visible in the image/video clips provided.

Thank you for this referral. If the clinical or image interpretation does not parallel your findings or if I can be of any further assistance please contact me.

**Sebastian Schaub**, Sebastian Schaub, DVM, Dr. med. vet. DipECVDI  
sebast.schaub@gmail.com