



PATIENT PRESENTING CLINICAL SIGNS

Max Heins owner saw him eat part of her charger , soft stool but no vomiting or diarrhea , we did a radiograph study yesterday and today (24 hours apart) , hx of neutering 10 days ago but I can feel a testicle in scrotal sac, ate last night and this morning , he is acting very normal.

SPECIES Abnormal PE/Chem/CBC/UA Results: Periodontal disease ,mild abdominal discomfort , few warts over the skin, no blood work done recently .

Canine

RADIOGRAPHIC STUDY OF THE ABDOMEN

BREED

A consecutive radiographic study of the abdomen in orthogonal imaging planes is provided for review. Radiographs are dated 11/20/22 and 11/21/22.

Shih Tzu

RADIOGRAPHIC FINDINGS

Multifocal spondylosis formation is seen along the lumbar spine.

SEX

No abnormalities of the extraabdominal soft tissues are noted. The abdominal wall is smooth and thin.

Male

Multiple surgical stapler rows are superimposed on the structures of the caudal abdomen.

AGE

The hepatic volume is moderately increased and the liver is protruding caudally beyond the costal arch; the caudoventral margins are rounded. The liver has a homogeneous soft tissue opacity. The gastric axis is oriented caudally.

14 Years

INTERPRETED BY

The splenic head is in the anticipated position and within normal limits for size and opacity. The splenic body and tail are considered normal for position, size, shape and opacity.

Sebastian Schaub, DVM
Dr. med. vet. DipECVDI

Both kidneys are seen and present with normal size, shape, delineation and opacity. The urinary bladder is in its anticipated position. No radiopaque calculi are noted throughout the upper and lower urinary tract.

HOSPITAL NAME

Lakeshore Woods
Animal Hospital

In the radiographic study dated 11/20/22, a mineral opaque rectangular shaped body is superimposed on the pyloric region of the stomach; measuring 1.8 cm in size. In the follow up study dated 11/21/22 the geometric body cannot be appreciated anymore.

The small intestinal loops are of even diameter and non-dilated, a small amount of gas is seen within the small intestinal loops and considered within normal limits.

REFERRING VET

Dr. Sam Masoud

The colon is seen in the expected position and presents with appropriate content. The cecum is moderately distended by gas.

RADIOGRAPHIC DIAGNOSIS

INVOICE

55308

- Gastric foreign body
- Hepatomegaly
- Suspect history of surgical intervention with use of a surgical stapler
- Spondylosis deformans

DATE

11-21-22

INTERPRETATION OF THE FINDINGS & FURTHER RECOMMENDATIONS

In the initial radiographic study, a geometric body can be appreciated in the stomach – can be a piece of plastic. The geometric body is not appreciated anymore in the follow up study of the abdomen and might have already passed the gastrointestinal tract. There is no evidence of



PATIENT

Max Heins

gastrointestinal mechanical obstruction. If vomiting develops, recommend follow up radiographs or a complete abdominal ultrasound examination.

Potentials for the hepatomegaly include metabolic hepatic disease/steroid induced hepatopathy, hepatitis or neoplastic infiltration. Ultrasound including FNA sampling can be used as minimally advanced diagnostic tests.

SPECIES

Canine

BREED

Shih Tzu

SEX

Male

AGE

14 Years

INTERPRETED BY

Sebastian Schaub, DVM
Dr. med. vet. DipECVDI

HOSPITAL NAME

Lakeshore Woods
Animal Hospital

REFERRING VET

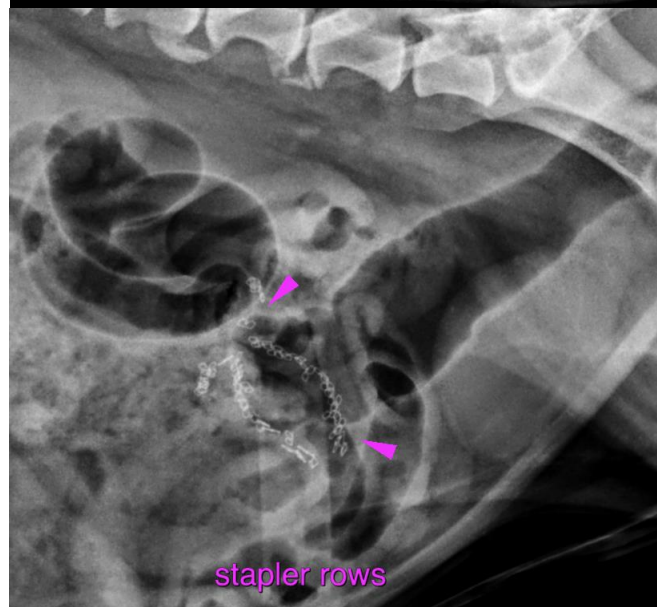
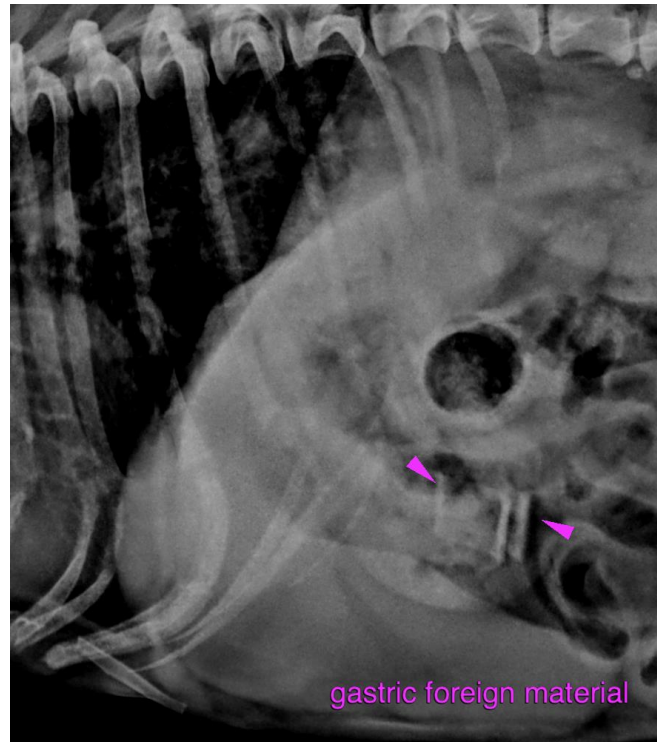
Dr. Sam Masoud

INVOICE

55308

DATE

11-21-22





PATIENT

Max Heins

SPECIES

Canine

BREED

Shih Tzu

SEX

Male

AGE

14 Years

INTERPRETED BY

Sebastian Schaub, DVM
Dr. med. vet. DipECVDI

HOSPITAL NAME

Lakeshore Woods
Animal Hospital

REFERRING VET

Dr. Sam Masoud

INVOICE

55308

DATE

11-21-22

The information and recommendations provided are based on the images presented by the referring veterinarian/sonographer. No evaluation can be communicated regarding pathology that was not visible in the image/video clips provided.

Thank you for this referral. If the clinical or image interpretation does not parallel your findings or if I can be of any further assistance please contact me.

Sebastian Schaub, Sebastian Schaub, DVM, Dr. med. vet. DipECVDI
sebast.schaub@gmail.com