



## PATIENT

Sadie O'niell

## SPECIES

Canine

## BREED

Mixed

## SEX

Female Spayed

## AGE

6Y

## WEIGHT

44.7kg

## INTERPRETED BY

Sebastian Schaub, DVM  
Dr. med. vet.  
DipECVDI

## IMAGING PERFORMED BY

MAG/MP

## HOSPITAL NAME

Green Dog Dental and  
Wellness

## REFERRING VET

Dr. Michael Geist

## INVOICE

72686

## DATE

11-20-25

## PRESENTING CLINICAL SIGNS

MUSCULOSKELETAL: Decreased ROM of hindlimbs and hips bilaterally, thickening of stifles bilaterally R>L. Abnormal gait initially, but improves once warmed up and walking around for a while. Ambulatory x 4. Mild pain on rising and sitting. COAT/SKIN: 1) Focal cyst like nodular firm mass on left dorsum of back; 1.5 cm x 2 cm; 2) cyst like nodular mass located on mid dorsal back easily expressed foreign material and cells 3) cyst like nodular mass located on left dorsal hind limb/left hip easily expressed foreign material and cells; Skin/coat is otherwise normal. Bright and shiny coat. No alopecia  
Abnormal PE/Chem/CBC/UA Results: Osteolytic lesions of the right distal femur with periosteal changes of the right stifle and spinous processes of the vertebral column Alveolar pattern and severe opaque - soft tissue like opacity in the caudal subsegment of the left cranial lob and the left caudal lung lobes Multifocal alveolar pattern noted; discussed possible pneumonia

## RADIOGRAPHIC STUDY OF THE THORAX & STIFLE JOINTS

Radiographs of the thorax in three imaging planes and a mediolateral view of the right stifle joint are provided for review.

## RADIOGRAPHIC FINDINGS

### Thorax

The spinous processes along the thoracic spine present multiple sites with contact lesions

The extrathoracic soft tissues present homogeneous without abnormalities.

The heart is of normal size and shape; there is no evidence of cardiac chamber or vascular enlargement. The pulmonary vasculature is within normal limits.

The cranial mediastinum presents the expected soft tissue opacity. The mediastinal width is less than twice the width of the vertebral column at the same level.

The trachea is normal in diameter and presents the anticipated course. The luminal outline of the trachea is smooth.

The left cranial lung lobe - cranial & caudal segment - and the left caudal lung lobe present intraparenchymal, well-defined, consolidation lesion with convex margins and distortion/compression of the affected bronchi.

The diaphragm is well delineated with even surface and the expected mild cranial bulging of the diaphragmatic cupola.

### Right stifle joint

The periarticular bones of the right stifle joint present mild to moderate osteophyte new bone formation. The distal fifth of the right femur presents a coarse trabecular pattern. The right stifle joint presents a moderate intracapsular soft tissue swelling, effacing the infrapatellar fat pad cranially and distorting the fascial plane caudally.

## RADIOGRAPHIC DIAGNOSIS

- Multiple pulmonary soft tissue masses left lung
- Coarse trabecular pattern distal segment right femur
- Moderate osteoarthritis right stifle joint
- Articular soft tissue swelling right stifle joint



## PATIENT

Sadie O'niell

## SPECIES

Canine

## BREED

Mixed

## SEX

Female Spayed

## AGE

6Y

## WEIGHT

44.7kg

## INTERPRETED BY

Sebastian Schaub, DVM  
Dr. med. vet.  
DipECVDI

## IMAGING PERFORMED BY

MAG/MP

## HOSPITAL NAME

Green Dog Dental and  
Wellness

## REFERRING VET

Dr. Michael Geist

## INVOICE

72686

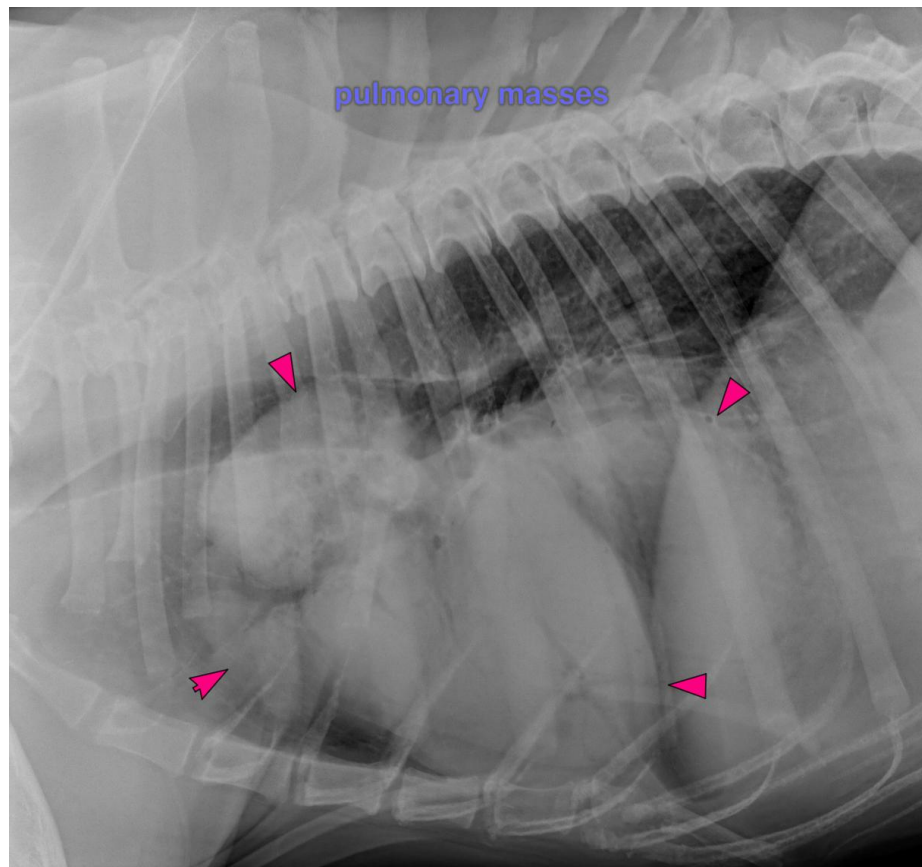
## DATE

11-20-25

## INTERPRETATION OF THE FINDINGS & FURTHER RECOMMENDATIONS

The pulmonary findings are consistent with primary or less likely secondary pulmonary neoplasia – such as histiocytic sarcoma or carcinoma. FNA sampling of the pulmonary masses can be performed for specification.

The coarse trabecular pattern of the distal aspect of the right femur can be accentuated by the osteophyte new bone formation and the diagnosis of aggressive osteolytic bone lesions (e.g. metastasis), is not definitive as the peripheral new bone formation are solid and well-defined and the included distal segment of the right femur shows comparable findings – secondary to degenerative joint disease, underlying pathology of the cranial cruciate ligament ± meniscal pathology is most likely.





## PATIENT

Sadie O'niell

## SPECIES

Canine

## BREED

Mixed

## SEX

Female Spayed

## AGE

6Y

## WEIGHT

44.7kg

## INTERPRETED BY

Sebastian Schaub, DVM  
Dr. med. vet.  
DipECVDI

## IMAGING PERFORMED BY

MAG/MP

## HOSPITAL NAME

Green Dog Dental and  
Wellness

## REFERRING VET

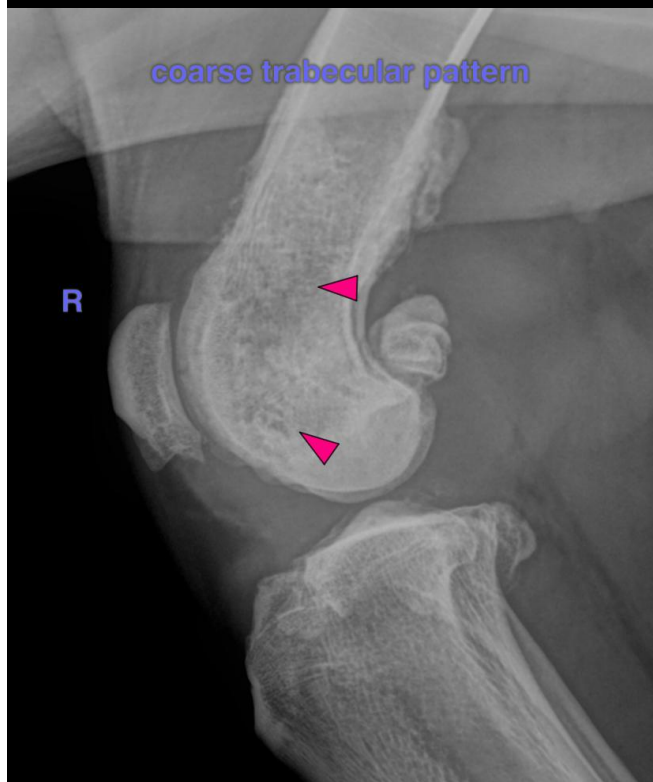
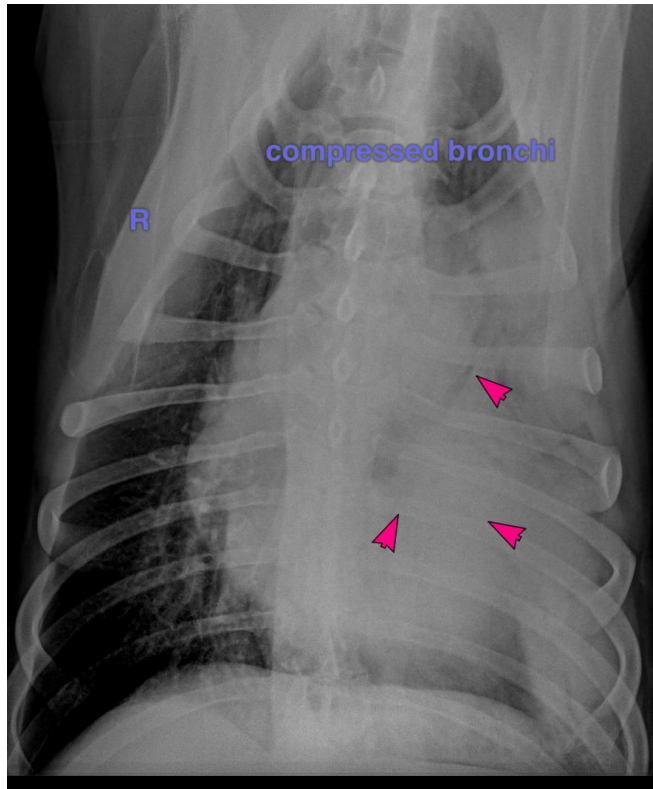
Dr. Michael Geist

## INVOICE

72686

## DATE

11-20-25





## PATIENT

Sadie O'niell

## SPECIES

Canine

## BREED

Mixed

## SEX

Female Spayed

## AGE

6Y

## WEIGHT

44.7kg

## INTERPRETED BY

Sebastian Schaub, DVM  
Dr. med. vet.  
DipECVDI

## IMAGING PERFORMED BY

MAG/MP

## HOSPITAL NAME

Green Dog Dental and  
Wellness

## REFERRING VET

Dr. Michael Geist

## INVOICE

72686

## DATE

11-20-25

The information and recommendations provided are based on the images presented by the referring veterinarian/sonographer. No evaluation can be communicated regarding pathology that was not visible in the image/video clips provided.

Thank you for this referral. If the clinical or image interpretation does not parallel your findings or if I can be of any further assistance please contact me.

**Sebastian Schaub**, Sebastian Schaub, DVM, Dr. med. vet. DipECVDI  
[info@sonopath.com](mailto:info@sonopath.com)