



PATIENT

Ashley Campos

SPECIES

Canine

BREED

Maltese

SEX

FS

AGE

11Y

WEIGHT

6lbs

INTERPRETED BY

Sebastian Schaub, DVM
Dr. med. vet.
DipECVDI

IMAGING PERFORMED BY

Jose Lopez

HOSPITAL NAME

Westchester Animal
Hospital

REFERRING VET

Randy Dominguez

INVOICE

72699

DATE

11-20-25

PRESENTING CLINICAL SIGNS

Presented with a mild proptosis of the right eye and elevated intraocular pressure. (90mg/hg)
Abnormal PE/Chem/CBC/UA Results:

COMPUTED TOMOGRAPHY OF THE SKULL

A high resolution pre- and post-contrast CT study of the skull is provided for review.

COMPUTED TOMOGRAPHIC FINDINGS

Multiple teeth are absent. Mineral attenuating material is attached to the crowns of multiple teeth.

The nasal cavity presents the expected aerated spaces between thin & even conchae and turbinates with smooth mucosal lining.

The volume of the right ocular bulb is moderately increased in comparison to the left ocular bulb.

Both temporomandibular joints present congruent joint spaces with even subchondral bone surfaces and are considered within normal limits.

Both tympanic bullae are aerated, the mucosal lining is not seen, the bony wall is smooth and thin. The external ear canals are within normal limits.

The brain presents no deviation from normal anatomy and symmetry. The brain parenchyma is homogeneous and within normal limits for attenuation and distribution of contrast enhancement. The ventricular system is non-dilated and symmetric.

The submandibular and medial retropharyngeal lymph nodes are small and elongated with a normal short-to-long-axis-ratio is < 0.5, the attenuation and contrast enhancement pattern is uniform.

COMPUTED TOMOGRAPHIC DIAGNOSIS

- History of right sided buphthalmos
- Dental tartar
- Multiple absent teeth

INTERPRETATION OF THE FINDINGS & FURTHER RECOMMENDATIONS

The CT study reveals no abnormalities that do explain the right sided glaucoma. There is no evidence of an intraocular mass.



PATIENT

Ashley Campos

SPECIES

Canine

BREED

Maltese

SEX

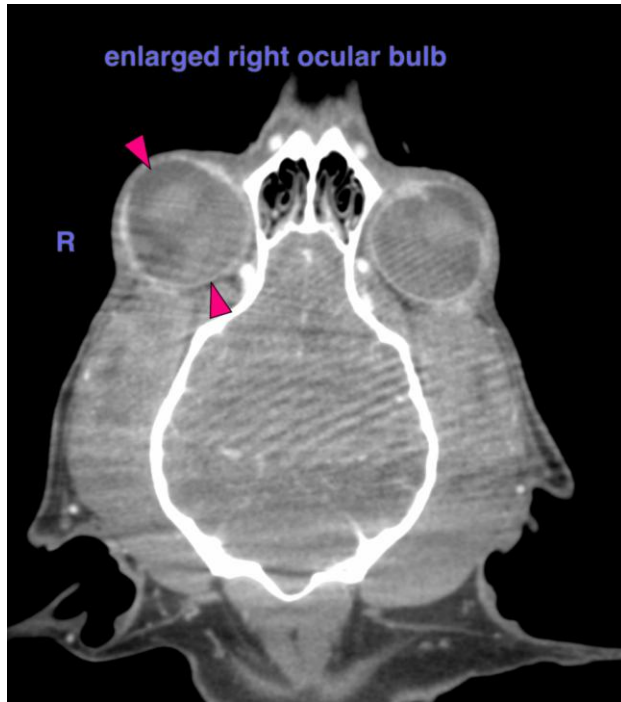
FS

AGE

11Y

WEIGHT

6lbs



INTERPRETED BY

Sebastian Schaub, DVM
Dr. med. vet.
DipECVDI

IMAGING PERFORMED BY

Jose Lopez

HOSPITAL NAME

Westchester Animal
Hospital

REFERRING VET

Randy Dominguez

INVOICE

72699

DATE

11-20-25

The information and recommendations provided are based on the images presented by the referring veterinarian/sonographer. No evaluation can be communicated regarding pathology that was not visible in the image/video clips provided.

Thank you for this referral. If the clinical or image interpretation does not parallel your findings or if I can be of any further assistance please contact me.

Sebastian Schaub, Sebastian Schaub, DVM, Dr. med. vet. DipECVDI
info@sonopath.com