



**PATIENT**

Violet Jarit

**PRESENTING CLINICAL SIGNS**

Pre-whelp radiographs. P due soon per O.

**SPECIES**

Canine

**RADIOGRAPHIC STUDY OF THE ABDOMEN**

Radiographs of the abdomen in two imaging planes are provided for review.

**BREED**

Shetland Sheepdog

**RADIOGRAPHIC FINDINGS**

The surrounding bony structures are within normal limits.

**SEX**

Female

No abnormalities of the extraabdominal soft tissues are noted. The abdominal wall is smooth and thin.

**AGE**

7 Years

The serosal detail is maintained throughout the peritoneal and retroperitoneal space.

The liver is appropriate in position, size and presents uniform opacity.

The splenic head is in the anticipated position and within normal limits for size and opacity. The splenic body and tail are considered normal for position, size, shape and opacity.

Both kidneys are seen and present with normal size, shape, delineation and opacity. The urinary bladder is in its anticipated position. No radiopaque calculi are noted throughout the upper and lower urinary tract.

Two mineralized fetal skeletal structures are seen in the uterine horns – the phalanges are mineralized.

**INTERPRETED BY**

Sebastian Schaub, DVM  
Dr. med. vet. DipECVDI

The stomach is in its anticipated position and presents normal content.

The small intestinal loops are deviated dorsally by the prominent uterine horns.

The colon is seen in the expected position and presents with appropriate content.

**HOSPITAL NAME**

The Pet Hospital of  
Stratford

**RADIOGRAPHIC DIAGNOSIS**

- Two mineralized fetal skeletal structures are appreciated

**REFERRING VET**

Dr. Claudia Giuliani

**INTERPRETATION OF THE FINDINGS & FURTHER RECOMMENDATIONS**

Two fetuses can be appreciated. Regarding the degree of mineralization of the skeletal structures, time to parturition is approximately 2-9 days.

**INVOICE**

54929

**DATE**

11-2-22



**PATIENT**

Violet Jarit

**SPECIES**

Canine

**BREED**

Shetland Sheepdog

**SEX**

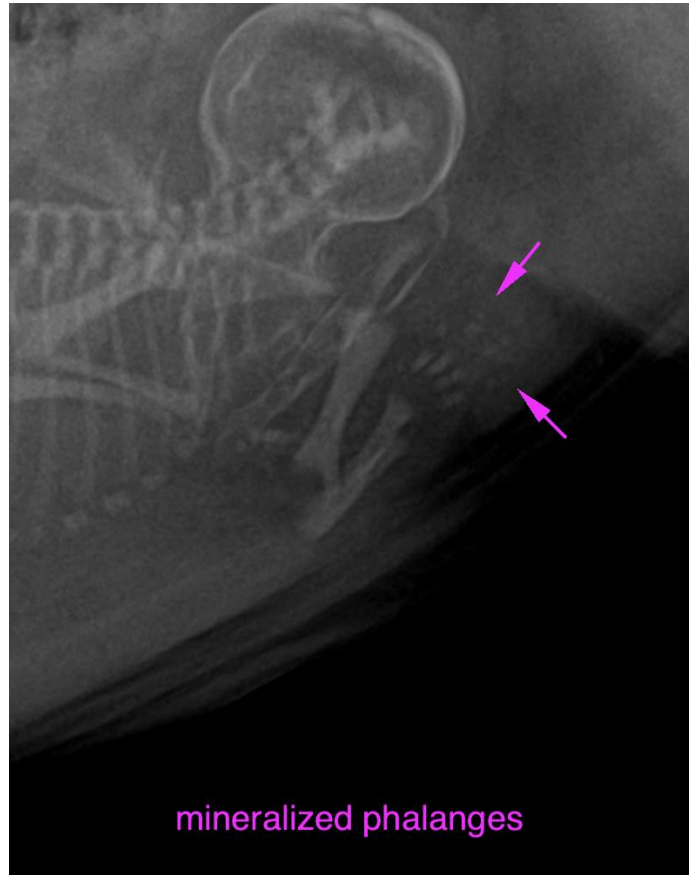
Female

**AGE**

7 Years

**INTERPRETED BY**

Sebastian Schaub, DVM  
Dr. med. vet. DipECVDI



mineralized phalanges

**HOSPITAL NAME**

The Pet Hospital of  
Stratford

**REFERRING VET**

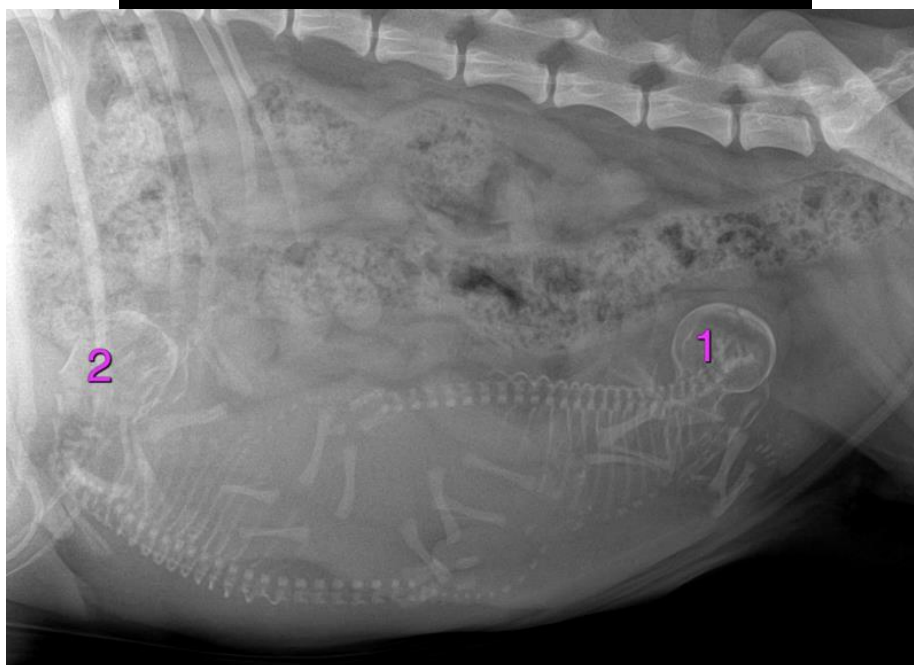
Dr. Claudia Giuliani

**INVOICE**

54929

**DATE**

11-2-22





**PATIENT**

Violet Jarit

**SPECIES**

Canine

The information and recommendations provided are based on the images presented by the referring veterinarian/sonographer. No evaluation can be communicated regarding pathology that was not visible in the image/video clips provided.

**BREED**

Shetland Sheepdog

Thank you for this referral. If the clinical or image interpretation does not parallel your findings or if I can be of any further assistance please contact me.

**Sebastian Schaub**, Sebastian Schaub, DVM, Dr. med. vet. DipECVDI  
sebast.schaub@gmail.com

**SEX**

Female

**AGE**

7 Years

**INTERPRETED BY**

Sebastian Schaub, DVM  
Dr. med. vet. DipECVDI

**HOSPITAL NAME**

The Pet Hospital of  
Stratford

**REFERRING VET**

Dr. Claudia Giuliani

**INVOICE**

54929

**DATE**

11-2-22