

**PATIENT PRESENTING CLINICAL SIGNS**

Karla Moldes Serious nasal discharge that has been reoccurring for months

COMPUTED TOMOGRAPHY OF THE SKULL

SPECIES A high resolution plain CT study of the skull is provided for review.

Lagamorph **COMPUTED TOMOGRAPHIC FINDINGS**

The pictured parts of the dentition are complete and unremarkable in all jaw quadrants.

BREED Advanced destruction of the nasal conchal structures bilaterally is appreciated, and soft tissue material is attached to the nasal mucosal lining. In the left nasal cavity, multiple, varying sized strong mineral attenuating bodies, measuring up to 2.2 mm in diameter are appreciated. In the rostradorsal aspect of the right nasal cavity, three small mineralized bodies measuring <1.9 mm are noted.

Rabbit

SEX Both temporomandibular joints present congruent joint spaces with even subchondral bone surfaces and are considered within normal limits.

S Both tympanic bullae are aerated, the mucosal lining is not seen, the bony wall is smooth and thin. The external ear canals are within normal limits.

AGE **COMPUTED TOMOGRAPHIC DIAGNOSIS**

- 5.3 Years
- Destructive rhinitis with multiple rhinoliths
 - Normal dentition
 - No evidence of otitis media or externa

INTERPRETED BY

Sebastian Schaub, DVM
Dr. med. vet. DipECVDI

INTERPRETATION OF THE FINDINGS & FURTHER RECOMMENDATIONS

The CT findings are consistent with chronic destructive – Pasteurella related rhinitis is most common. There is evidence of multiple rhinoliths in the nasal cavities, L>R. The latter can serve as a reservoir for the bacterial infection and are a potential trigger for recurrent upper airway infection – surgical management to remove the rhinoliths should be considered.

HOSPITAL NAME

Mobile Pet Imaging

REFERRING VET

Meaux

INVOICE

54932

DATE

11-2-22



PATIENT

Karla Moldes

SPECIES

Lagamorph

BREED

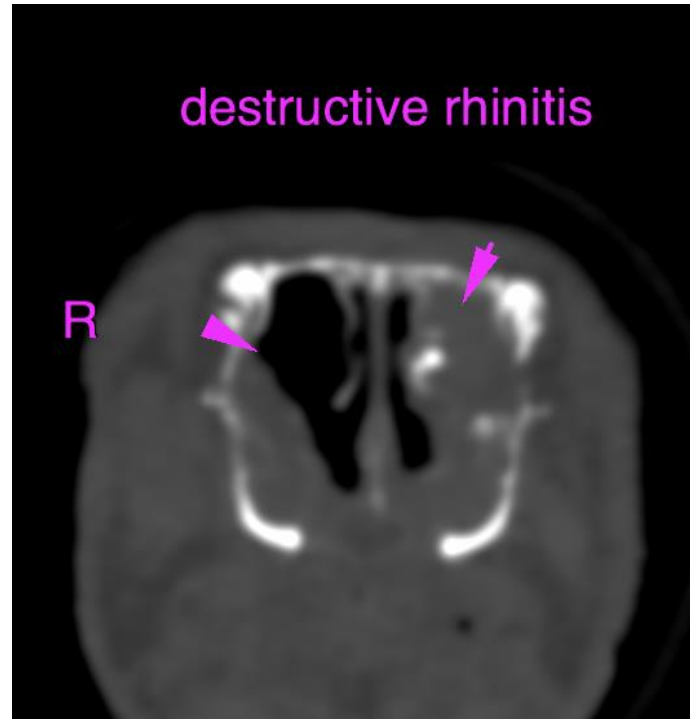
Rabbit

SEX

S

AGE

5.3 Years



INTERPRETED BY

Sebastian Schaub, DVM
Dr. med. vet. DipECVDI

HOSPITAL NAME

Mobile Pet Imaging

REFERRING VET

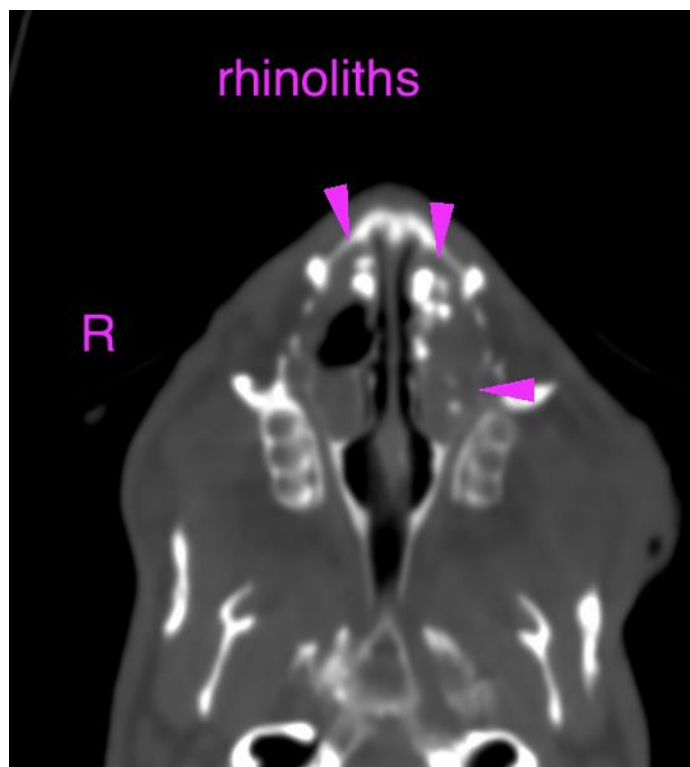
Meaux

INVOICE

54932

DATE

11-2-22



**PATIENT**

Karla Moldes

SPECIES

Lagamorph

The information and recommendations provided are based on the images presented by the referring veterinarian/sonographer. No evaluation can be communicated regarding pathology that was not visible in the image/video clips provided.

Thank you for this referral. If the clinical or image interpretation does not parallel your findings or if I can be of any further assistance please contact me.

BREED

Rabbit

Sebastian Schaub, Sebastian Schaub, DVM, Dr. med. vet. DipECVDI
sebast.schaub@gmail.com

SEX

S

AGE

5.3 Years

INTERPRETED BY

Sebastian Schaub, DVM
Dr. med. vet. DipECVDI

HOSPITAL NAME

Mobile Pet Imaging

REFERRING VET

Meaux

INVOICE

54932

DATE

11-2-22