



PATIENT PRESENTING CLINICAL SIGNS

PATIENT
James Bravo

SPECIES
Canine

New dog to o, got about 4-5 weeks ago. O reports pt snores and seems to have more effect to breathe, especially when eating and sleeping. Pt has been like that since she got her. Pt presented today for not eating for about 2 days, not even interested in people food or treats. O reports pt vomited mucousy looking vomit once this morning. Pt has been lethargic and moaning a lot. O thinks she's in heat, because she is noticing blood tinge on her beds. Pt has bloody diarrhea yesterday, but hasn't had a movement since.

RADIOGRAPHIC STUDY OF THE THORAX & ABDOMEN

BREED
Beagle

A complete set of radiographs of the thorax and abdomen is provided for review.

RADIOGRAPHIC FINDINGS

The body condition score is 8/9.

SEX
Thorax

Female Intact
The surrounding bony structures are within normal limits.

The extrathoracic soft tissues present homogeneous without abnormalities. The laryngeal structures are mildly mineralized.

AGE

9 Years
The heart is of normal size and shape, there is no evidence of cardiac chamber or vascular enlargement. The pulmonary vasculature is within normal limits.

INTERPRETED BY
The cranial mediastinum is moderately widened by fat.

Sebastian Schaub, DVM
Dr. med. vet. DipECVDI
The trachea is normal in diameter and presents the anticipated course. The luminal outline of the trachea is smooth.

HOSPITAL NAME
The bronchial tree presents with thin walls and tapers uniformly towards the periphery as expected.

The Pet Hospital of Stratford
The lung parenchyma presents the expected architecture and a generalized moderate ground glass opacification of the lung parenchyma, due to the nutritional status; the intrapulmonary vascular branching is blurred by the generalized increased radiopacity of the lung parenchyma.

REFERRING VET
The diaphragm is well delineated with even surface and the expected mild cranial bulging of the diaphragmatic cupola.

Dr. Claudia Giuliani
Abdomen

The surrounding bony structures are within normal limits.

INVOICE
54951
No abnormalities of the extraabdominal soft tissues are noted. The abdominal wall is smooth and thin.

The serosal detail is maintained throughout the peritoneal and retroperitoneal space.

DATE
11-2-22
The hepatic volume is mild to moderately increased and the liver is mildly protruding caudally beyond the costal arch. The caudoventral hepatic margins are rounded.

The splenic head is in the anticipated position and within normal limits for size and opacity. The splenic body and tail are considered normal for position, size, shape and opacity.



PATIENT

James Bravo

Both kidneys are seen and present with normal size, shape, delineation and opacity. The urinary bladder is in its anticipated position. No radiopaque calculi are noted throughout the upper and lower urinary tract.

The stomach is in its anticipated position and presents normal content.

SPECIES

Canine

The small intestinal loops are of even diameter and non-dilated, a small amount of gas is seen within the small intestinal loops and considered within normal limits.

The colon is seen in the expected position and presents with appropriate content.

BREED

Beagle

RADIOGRAPHIC DIAGNOSIS

- Obesity
- Mild hepatomegaly

SEX

Female Intact

INTERPRETATION OF THE FINDINGS & FURTHER RECOMMENDATIONS

Potentials for the hepatomegaly include metabolic hepatic disease/steroid induced hepatopathy, hepatitis or neoplastic infiltration. Ultrasound including FNA sampling can be used as minimally advanced diagnostic tests.

AGE

9 Years

No specific abnormalities are appreciated, explaining the hypoxia. If not done so yet, recommend complementing workup by complete blood work including cpl to rule out underlying pancreatitis.

The uterine horns are not appreciated in the current set of radiographs.

INTERPRETED BY

Sebastian Schaub, DVM
Dr. med. vet. DipECVDI

The obesity can be a source for the respiratory noise, due to mass effect on the pharynx and is also a known predisposing factor for cough.

HOSPITAL NAME

The Pet Hospital of
Stratford

REFERRING VET

Dr. Claudia Giuliani

INVOICE

54951

DATE

11-2-22



PATIENT

James Bravo

SPECIES

Canine

BREED

Beagle

SEX

Female Intact

AGE

9 Years

INTERPRETED BY

Sebastian Schaub, DVM
Dr. med. vet. DipECVDI

HOSPITAL NAME

The Pet Hospital of
Stratford

REFERRING VET

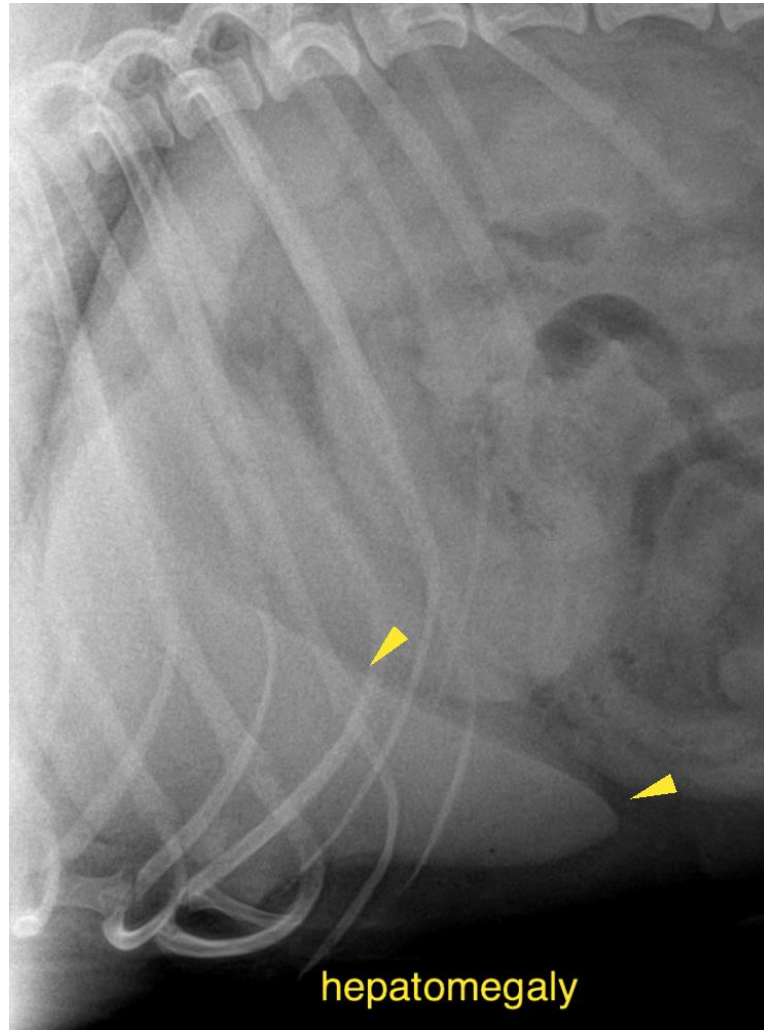
Dr. Claudia Giuliani

INVOICE

54951

DATE

11-2-22



The information and recommendations provided are based on the images presented by the referring veterinarian/sonographer. No evaluation can be communicated regarding pathology that was not visible in the image/video clips provided.

Thank you for this referral. If the clinical or image interpretation does not parallel your findings or if I can be of any further assistance please contact me.

Sebastian Schaub, Sebastian Schaub, DVM, Dr. med. vet. DipECVDI
sebast.schaub@gmail.com