

**PATIENT**

Zaios Reyes

SPECIES

Canine

BREED

Pit Bull Mix

PRESENTING CLINICAL SIGNS

THE OWNER COMPLAINED OF LIMPING ON THE FRONT LEFT LEG. It has been going for about 1 month. He is not painful in the joints, neck or any were on his legs. The legs seem to be the same size. The pads on the left front foot are softer and thinner than the front right foot. I could not detect a limp on walking or trotting. The owner said when he gets up from a nap or in the morning he obviously limps. As he starts to move around the limp goes away or is not real notable. If he plays with other dogs he starts to limp. He has been afraid to take him on walks because if a long walk he starts to limp. The only thing I would find on the radiographs was cortical bone thickening on the shaft of the ulna and the radius in both front legs. He is not painful in these areas but these areas seem to have less muscle tone than the upper leg. He has nice big shoulders but the lower legs seems to be smaller than what they should be compared to the upper leg.

RADIOGRAPHIC STUDY OF THE ELBOW JOINTS**SEX**

A complete set of radiographs of the elbow joints is provided for review.

MN

RADIOGRAPHIC FINDINGS**AGE**

There is a chondrodystrophic conformation of the osseous structures of the front limbs.

2 Years

The elbow joints bilaterally present with smooth margins of the subchondral bone. The joint space of both elbow joints is congruent. The surrounding soft tissue structures are within normal limits.

INTERPRETED BY

Sebastian Schaub, DVM
Dr. med. vet. DipECVDI

There is mild irregularity of the cranial cortex of the ulna bilaterally, level with the insertion of the interosseous ligament.

HOSPITAL NAME

Pet Med plus

RADIOGRAPHIC DIAGNOSIS

- Normal elbow joints
- Chondrodystrophic bone conformation

REFERRING VET

Dr. Donita McElroy

INTERPRETATION OF THE FINDINGS & FURTHER RECOMMENDATIONS

The radiographic study of the elbow joints presents without abnormalities.

INVOICE

48166

DATE

11-2-21



PATIENT

Zaios Reyes

SPECIES

Canine

BREED

Pit Bull Mix

SEX

MN

AGE

2 Years

INTERPRETED BY

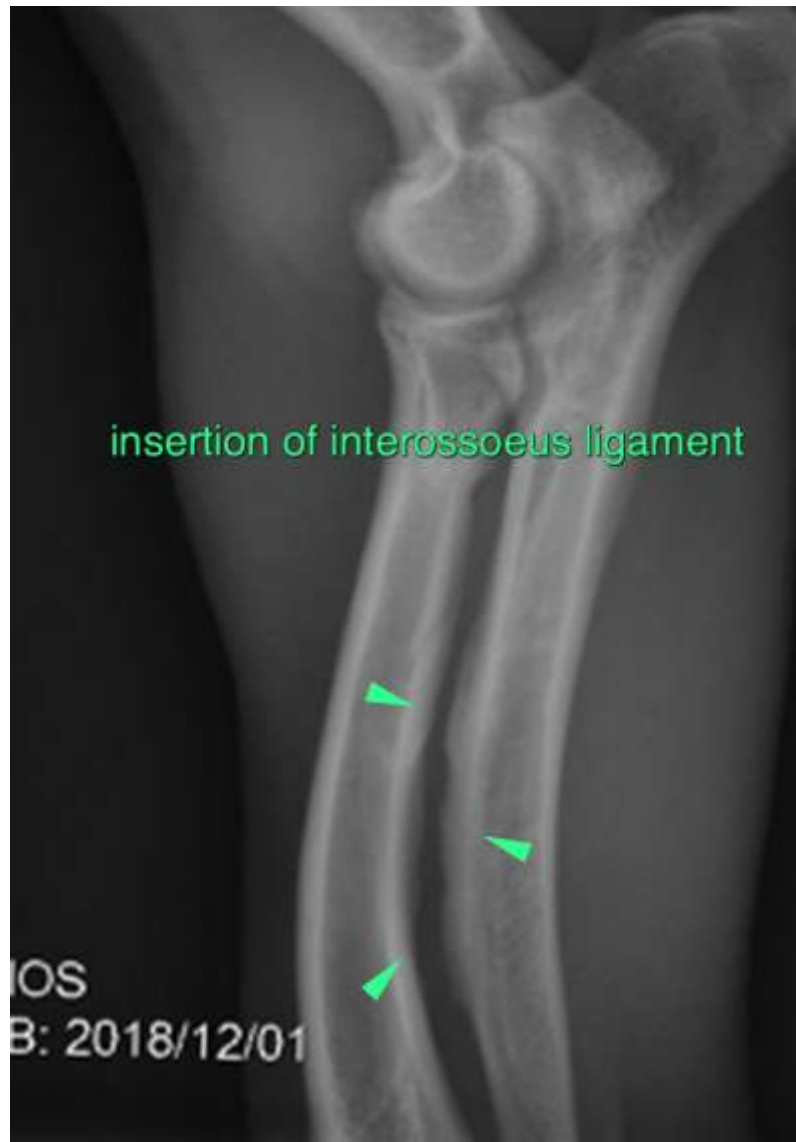
Sebastian Schaub, DVM
Dr. med. vet. DipECVDI

HOSPITAL NAME

Pet Med plus

REFERRING VET

Dr. Donita McElroy



INVOICE

48166

DATE

11-2-21

The information and recommendations provided are based on the images presented by the referring veterinarian. No evaluation can be communicated regarding pathology that was not visible in the image/video clips provided.

Thank you for this referral. If the clinical or image interpretation does not parallel your findings or if I can be of any further assistance please contact me.

Sebastian Schaub, Sebastian Schaub, DVM, Dr. med. vet. DipECVDI
sebast.schaub@gmail.com