

**PATIENT**

Watson Ciomber

PRESENTING CLINICAL SIGNS

Has been limping on and off on the right front leg. Watson was out playing ball last Friday and really hurt his right front leg. We has not been putting any weight on the front leg. It was getting better and then was playing with his sister this morning and re-hurt himself.

SPECIES

Canine

Abnormal PE/Chem/CBC/UA Results: PE: LAME ON RIGHT FRONT, DECREASED MUSCLE MASS ON RIGHT SHOULDER, PAINFUL TO PALPATION AND MANIPULATION OF RIGHT SHOULDER. healthy other than that. No resent labs done.

BREED

Vizsla

RADIOGRAPHIC STUDY OF THE SHOULDER & ELBOW JOINTS

A full set of radiographs of the shoulder joints and elbow joints is provided for review.

SEX

Neutered

Both shoulder joints present smooth osseous margins and the surrounding soft tissue structures are within normal limits.

The elbow joints present smooth osseous margins and a well-defined contour of the medial coronoid process, unremarkable.

AGE

1 Year, 3 Months

RADIOGRAPHIC DIAGNOSIS

- Normal shoulder joints
- Normal elbow joints

INTERPRETED BY

Sebastian Schaub, DVM
Dr. med. vet. DipECVDI

INTERPRETATION OF THE FINDINGS & FURTHER RECOMMENDATIONS

The radiographic study of the shoulder & elbow joints presents without abnormalities. Consider a clinical trial with NSAIDs and rest for 2 weeks. If clinical signs are refractory to therapy, re-evaluating the patient is recommended. If there is strong clinical suspicion for pathology of the bicipital tendon or rotator cuff injury, an ultrasound examination of the affected shoulder joint can be performed for further workup.

HOSPITAL NAME

Elizabeth Animal
Hospital

REFERRING VET

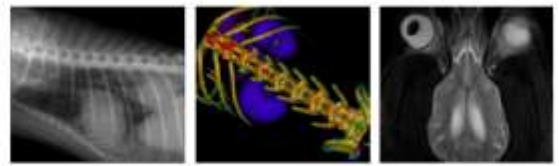
Kim Allyn, DVM

INVOICE

48164

DATE

11-2-21



PATIENT

Watson Ciomber

The information and recommendations provided are based on the images presented by the referring veterinarian. No evaluation can be communicated regarding pathology that was not visible in the image/video clips provided.

Thank you for this referral. If the clinical or image interpretation does not parallel your findings or if I can be of any further assistance please contact me.

SPECIES

Canine

Sebastian Schaub, Sebastian Schaub, DVM, Dr. med. vet. DipECVDI
sebast.schaub@gmail.com

BREED

Vizsla

SEX

Neutered

AGE

1 Year, 3 Months

INTERPRETED BY

Sebastian Schaub, DVM
Dr. med. vet. DipECVDI

HOSPITAL NAME

Elizabeth Animal
Hospital

REFERRING VET

Kim Allyn, DVM

INVOICE

48164

DATE

11-2-21