



**PATIENT**

Puck Durnin

**PRESENTING CLINICAL SIGNS**

Owner reports 2 weeks of pet shaking and notable pelvic limb weakness. Pe revealed stiff neck upon flexion both directions. Sensitive to palpation T10-T11 and L3-4. Muscle atrophy in pelvic limbs.

**SPECIES**

Canine

**RADIOGRAPHIC STUDY OF THE COMPLETE SPINE**

Radiographs of the cervical, thoracic and lumbar spine in two imaging planes (thoracic & lumbar) are provided for review.

**BREED**

French Bulldog

**RADIOGRAPHIC FINDINGS**

The osseous and surrounding soft tissue structures of the cervical spine are within normal limits. T2, T5-T8 and T9 present as hemivertebra.

**SEX**

The intervertebral disc space T13/L1 is moderately narrowed.

NM

Superimposed on the ventral aspect of the neuroforamina L3/L4, L4/L5 and L5/L6 convex shaped, mild irregular mineralized material is visible.

**AGE**

10 Years

**RADIOGRAPHIC DIAGNOSIS**

- Discopathy T13/L1
- Possible mild intervertebral disc protrusion L3/L4 to L5/L6 versus lateral spondylosis formation
- Multiple hemivertebra thoracic spine

**INTERPRETED BY**

Sebastian Schaub, DVM  
Dr. med. vet. DipECVDI

**INTERPRETATION OF THE FINDINGS & FURTHER RECOMMENDATIONS**

The narrowed intervertebral disc space T13/L1 is compatible with discopathy ± compressive myelopathy. The mineralized material seen superimposed on the ventral aspect of the neuroforamina L3/L4 to L5/L6 can present protrusion of mineralized disc material, lateral spondylosis formation or mineralization of the overlying soft tissue structures (less likely). Cross-sectional imaging can be used for further workup and should be considered if neurological status deteriorate.

**HOSPITAL NAME**

Paws and Claws  
Urgent Care

**REFERRING VET**

Dr. Juarez

**INVOICE**

48168

**DATE**

11-2-21



**PATIENT**

Puck Durnin

**SPECIES**

Canine

**BREED**

French Bulldog

**SEX**

NM

**AGE**

10 Years

**INTERPRETED BY**

Sebastian Schaub, DVM  
Dr. med. vet. DipECVDI

**HOSPITAL NAME**

Paws and Claws  
Urgent Care

**REFERRING VET**

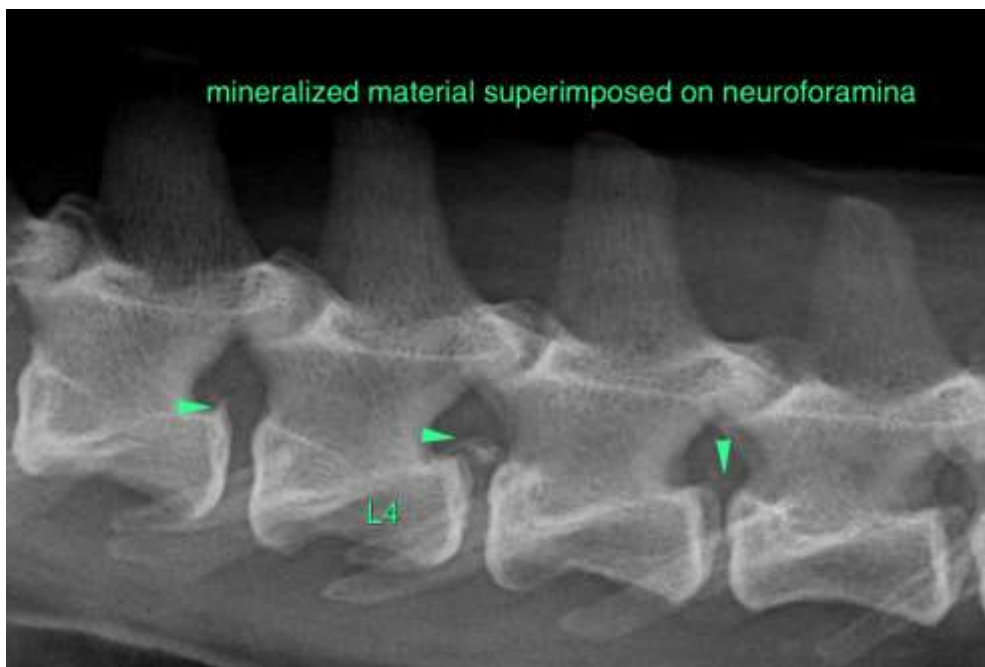
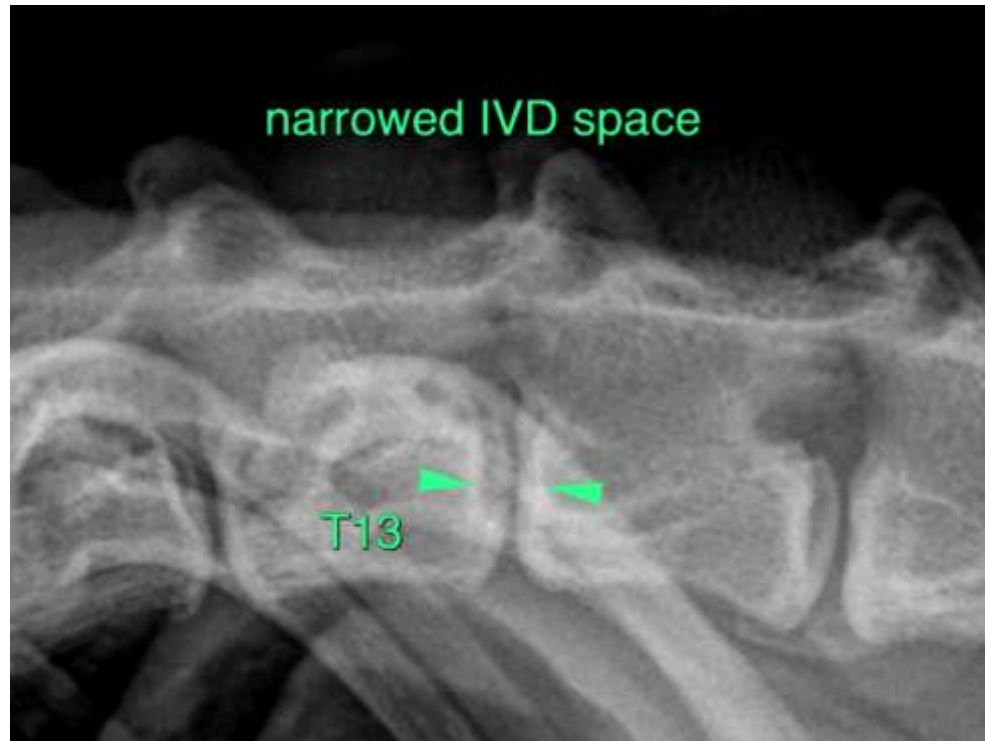
Dr. Juarez

**INVOICE**

48168

**DATE**

11-2-21





**PATIENT**

Puck Durnin

The information and recommendations provided are based on the images presented by the referring veterinarian. No evaluation can be communicated regarding pathology that was not visible in the image/video clips provided.

**SPECIES**

Canine

Thank you for this referral. If the clinical or image interpretation does not parallel your findings or if I can be of any further assistance please contact me.

**Sebastian Schaub**, Sebastian Schaub, DVM, Dr. med. vet. DipECVDI  
sebast.schaub@gmail.com

**BREED**

French Bulldog

**SEX**

NM

**AGE**

10 Years

**INTERPRETED BY**

Sebastian Schaub, DVM  
Dr. med. vet. DipECVDI

**HOSPITAL NAME**

Paws and Claws  
Urgent Care

**REFERRING VET**

Dr. Juarez

**INVOICE**

48168

**DATE**

11-2-21