



PATIENT

Andre Ferguson

PRESENTING CLINICAL SIGNS

P straining to defecate the last couple of days, no diarrhea prior. Still e/d ok. No vomit. Per o did not get into anything.

SPECIES

Canine

RADIOGRAPHIC STUDY OF THE ABDOMEN

Radiographs of the abdomen in three imaging planes are provided for review.

BREED

Poodle

RADIOGRAPHIC FINDINGS

The surrounding bony structures are within normal limits.

SEX

Neutered Male

No abnormalities of the extraabdominal soft tissues are noted. The abdominal wall is smooth and thin.

The serosal detail is maintained throughout the peritoneal and retroperitoneal space.

The liver is appropriate in position, size and presents uniform opacity.

The splenic head is in the anticipated position and within normal limits for size and opacity. The splenic body and tail are considered normal for position, size, shape and opacity.

AGE

8 Years

Both kidneys are seen and present with normal size, shape, delineation and opacity. The urinary bladder is in its anticipated position. No radiopaque calculi are noted throughout the upper and lower urinary tract.

INTERPRETED BY

Sebastian Schaub, DVM
Dr. med. vet. DipECVDI

The stomach is in its anticipated position and presents normal content.

The small intestinal loops are of even diameter and non-dilated, a small amount of gas is seen within the small intestinal loops and considered within normal limits.

The colon is seen in the expected position and presents with appropriate content.

HOSPITAL NAME

The Pet Hospital of
Stratford

RADIOGRAPHIC DIAGNOSIS

- Normal abdomen

REFERRING VET

Dr. Claudia Giuliani

INTERPRETATION OF THE FINDINGS & FURTHER RECOMMENDATIONS

The radiographic study of the abdomen presents without abnormalities. Recommend complementing workup by a digital rectal exam to rule out stricture or intramural rectal lesion.

INVOICE

55270

DATE

11-19-22



PATIENT

Andre Ferguson

SPECIES

Canine

BREED

Poodle

SEX

Neutered Male

AGE

8 Years

INTERPRETED BY

Sebastian Schaub, DVM
Dr. med. vet. DipECVDI

HOSPITAL NAME

The Pet Hospital of
Stratford

REFERRING VET

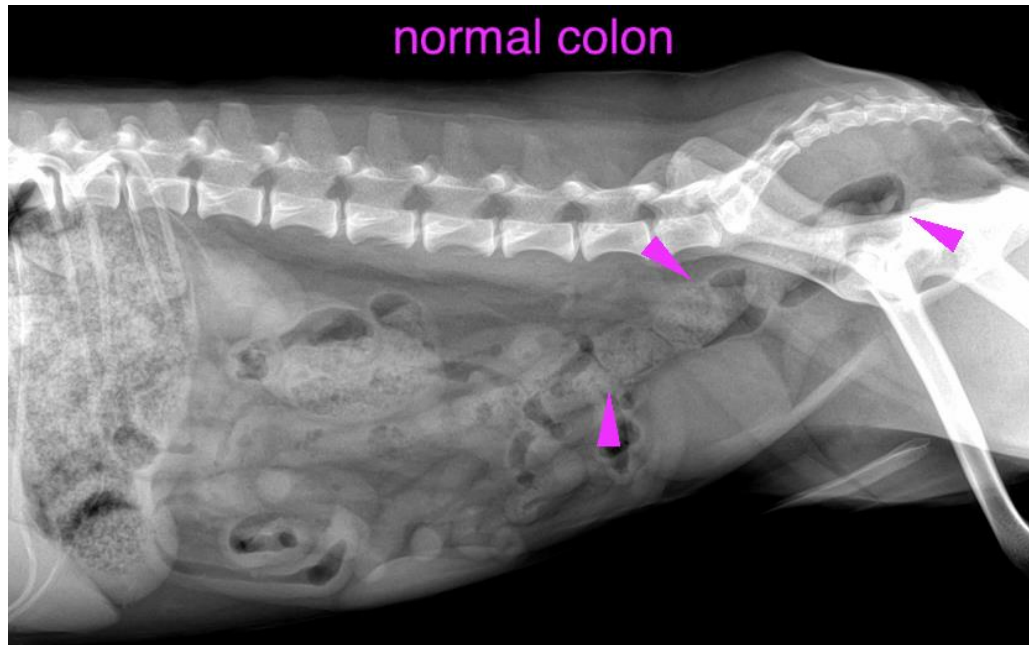
Dr. Claudia Giuliani

INVOICE

55270

DATE

11-19-22



The information and recommendations provided are based on the images presented by the referring veterinarian/sonographer. No evaluation can be communicated regarding pathology that was not visible in the image/video clips provided.

Thank you for this referral. If the clinical or image interpretation does not parallel your findings or if I can be of any further assistance please contact me.

Sebastian Schaub, Sebastian Schaub, DVM, Dr. med. vet. DipECVDI
sebast.schaub@gmail.com