



PATIENT

Lou Kazic

SPECIES

Canine

BREED

French Bulldog

SEX

Male Neutered

AGE

10Y, 5M

WEIGHT

14.5kg

INTERPRETED BY

Sebastian Schaub, DVM
Dr. med. vet.
DipECVDI

IMAGING PERFORMED BY

Lisa S.

HOSPITAL NAME

Animal Surgical Center
- Oceanside

REFERRING VET

Dr. Short

INVOICE

72669

DATE

11-18-25

PRESENTING CLINICAL SIGNS

Rostral mandibular mass (SCC) CT scan for evaluation of resectability and metastasis.

COMPUTED TOMOGRAPHY OF THE SKULL

A high resolution pre- and post-contrast CT study of the skull is provided for review.

COMPUTED TOMOGRAPHIC FINDINGS

The skull has a brachycephalic conformation with significant crowding and rotation of the maxillary premolar teeth.

Multiple teeth are absent. The crown of triadan 408 is absent and the retained roots presents zones with resorptive lesions.

Centered on the most rostral segment of the mandible bilaterally, an ill-defined soft tissue attenuating mass with a heterogeneous contrast enhancement pattern is seen. The associated alveolar bone of the mandibular incisor teeth bilaterally presents an ill-defined zone with permeative osteolytic lesions.

The nasal cavity presents the expected aerated spaces between thin & even conchae and turbinates with smooth mucosal lining. The soft palate is elongated – extending up to the level of the arytenoid cartilages – and thickened.

Both temporomandibular joints present congruent joint spaces with even subchondral bone surfaces and are considered within normal limits.

Both tympanic bullae are filled with non-contrast enhancing soft tissue material. The osseous wall of both tympanic bullae is thickened and smooth. The external ear canals are within normal limits.

The brain presents no deviation from normal anatomy and symmetry. The brain parenchyma is homogeneous and within normal limits for attenuation and distribution of contrast enhancement. The ventricular system is non-dilated and symmetric.

The submandibular and medial retropharyngeal lymph nodes are small and elongated with a normal short-to-long-axis-ratio is < 0.5, the attenuation and contrast enhancement pattern is uniform.

In the parenchyma of the left mandibular salivary gland a punctuate mineralization is noted.

COMPUTED TOMOGRAPHIC DIAGNOSIS

- History of squamous cell carcinoma rostral segment of mandible bilaterally with secondary polyostotic aggressive osteolysis of the rostral aspect of the right & left mandible
- Thickened and elongated soft palate
- Bilateral otitis media – suspect primary secretory
- Complicated dental fracture 408
- Multiple absent teeth

INTERPRETATION OF THE FINDINGS & FURTHER RECOMMENDATIONS

Complete surgical resection of the rostral mandibular mass via rostral mandibulectomy is considered feasible – potential osteotomy lines are distal to the mandibular canine teeth.

Consider complementing full tumor staging by FNA sampling of the regional lymph nodes of the skull.



PATIENT

Lou Kazic

SPECIES

Canine

BREED

French Bulldog

SEX

Male Neutered

AGE

10Y, 5M

WEIGHT

14.5kg

INTERPRETED BY

Sebastian Schaub, DVM
Dr. med. vet.
DipECVDI

IMAGING PERFORMED BY

Lisa S.

HOSPITAL NAME

Animal Surgical Center
- Oceanside

REFERRING VET

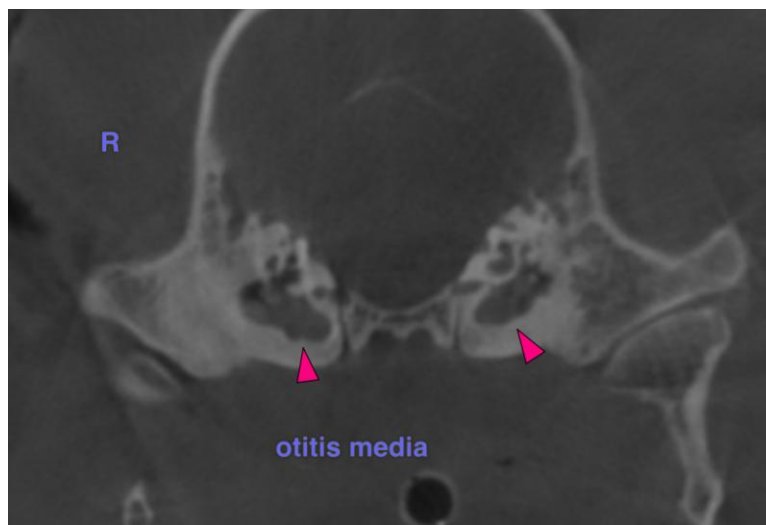
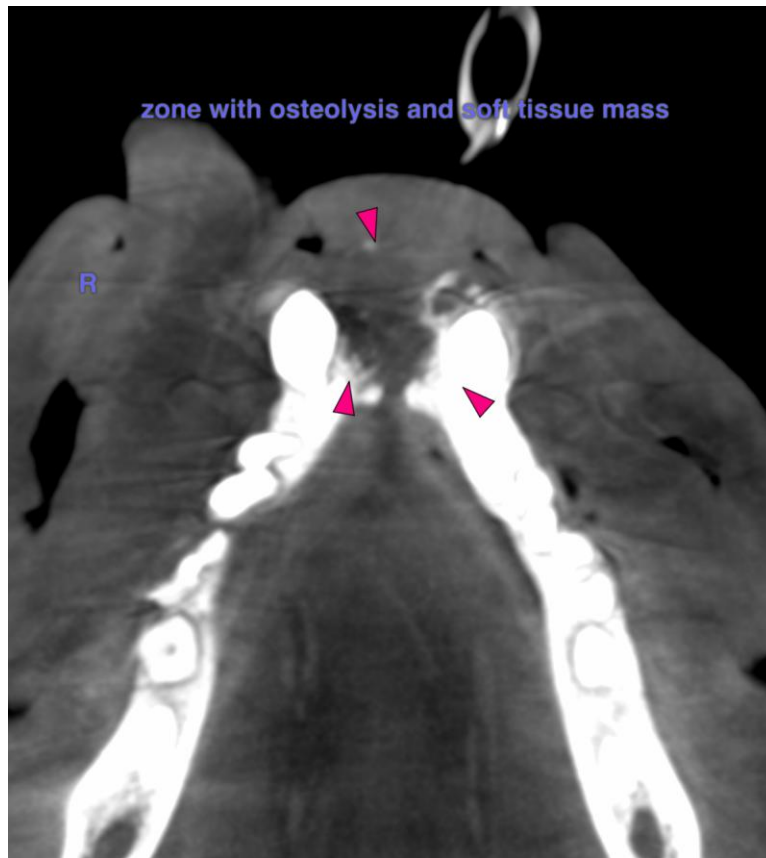
Dr. Short

INVOICE

72669

DATE

11-18-25





PATIENT

Lou Kazic

SPECIES

Canine

BREED

French Bulldog

SEX

Male Neutered

AGE

10Y, 5M

WEIGHT

14.5kg

INTERPRETED BY

Sebastian Schaub, DVM
Dr. med. vet.
DipECVDI

IMAGING PERFORMED BY

Lisa S.

HOSPITAL NAME

Animal Surgical Center
- Oceanside

REFERRING VET

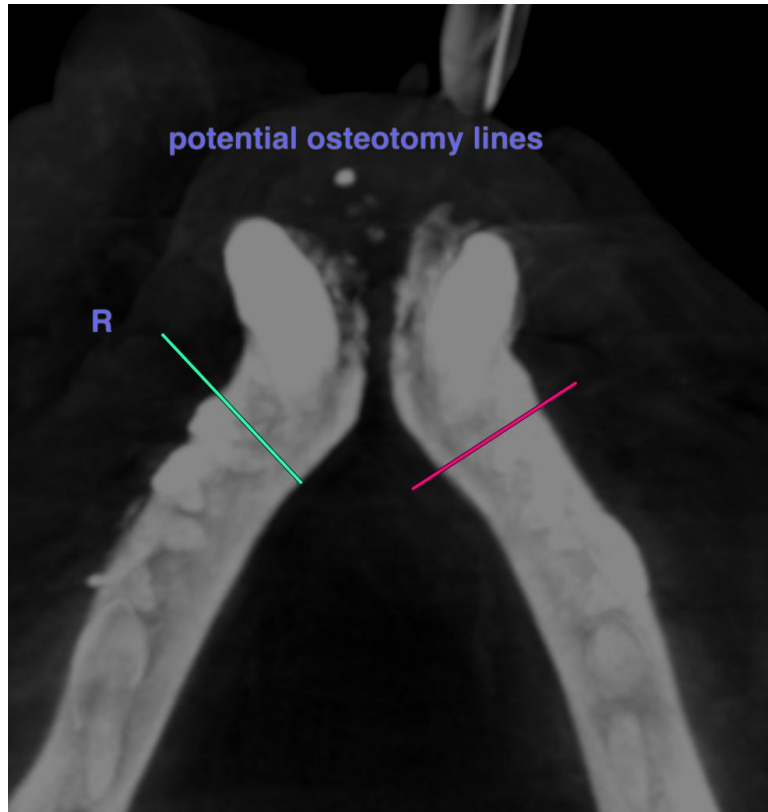
Dr. Short

INVOICE

72669

DATE

11-18-25



The information and recommendations provided are based on the images presented by the referring veterinarian/sonographer. No evaluation can be communicated regarding pathology that was not visible in the image/video clips provided.

Thank you for this referral. If the clinical or image interpretation does not parallel your findings or if I can be of any further assistance please contact me.

Sebastian Schaub, Sebastian Schaub, DVM, Dr. med. vet. DipECVDI
info@sonopath.com