


PATIENT PRESENTING CLINICAL SIGNS

Sophie Nicoara Two weeks nasal reverse sneezing

COMPUTED TOMOGRAPHIC STUDY OF THE SKULL
SPECIES

Canine

A high resolution pre- and post-contrast CT study of the skull is provided for review.

BREED

French Water Dog

COMPUTED TOMOGRAPHIC FINDINGS

The pictured parts of the dentition are complete and unremarkable in all jaw quadrants.

The nasal cavity presents the expected aerated spaces between thin & even conchae and turbinates with smooth mucosal lining.

SEX

Female

Both temporomandibular joints present congruent joint spaces with even subchondral bone surfaces and are considered within normal limits.

Both tympanic bullae are aerated, the mucosal lining is not seen, the bony wall is smooth and thin. The external ear canals are within normal limits.

AGE

3 Years

The brain presents no deviation from normal anatomy and symmetry. The brain parenchyma is homogeneous and within normal limits for attenuation and distribution of contrast enhancement. The ventricular system is non-dilated and symmetric.

The submandibular and medial retropharyngeal lymph nodes are small and elongated with a normal short-to-long-axis-ratio is < 0.5, the attenuation and contrast enhancement pattern is uniform.

INTERPRETED BY

Sebastian Schaub,
 DVM Dr. med. vet.
 DipECVDI

COMPUTED TOMOGRAPHIC DIAGNOSIS

- Normal skull, normal upper airways

HOSPITAL NAME

Animal Medical
 Center of Mt.
 Pleasant

INTERPRETATION OF THE FINDINGS & FURTHER RECOMMENDATIONS

The current CT study of the skull is negative for clinically relevant disease, the upper airways are aerated and no abnormalities are appreciated. Complementing workup by rhinoscopy including biopsy to rule out non-specific rhinitis, nasal mites or any other inflammatory trigger along the nasopharyngeal region can be considered as an advanced diagnostic test.

REFERRING VET

Dr. Steven Epstein

INVOICE

42857

DATE

11/18/22



PATIENT

Sophie Nicoara

SPECIES

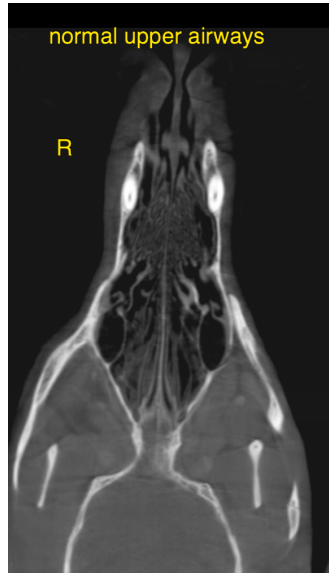
Canine

BREED

French Water Dog

SEX

Female



AGE

3 Years

The information and recommendations provided are based on the images presented by the referring veterinarian. No evaluation can be communicated regarding pathology that was not visible in the image/video clips provided.

Thank you for this referral. If the clinical or image interpretation does not parallel your findings or if I can be of any further assistance please contact me.

INTERPRETED BY

Sebastian Schaub,
DVM Dr. med. vet.
DipECVDI

Sebastian Schaub, Sebastian Schaub, DVM, Dr. med. vet. DipECVDI
sebast.schaub@gmail.com

HOSPITAL NAME

Animal Medical
Center of Mt.
Pleasant

REFERRING VET

Dr. Steven Epstein

INVOICE

42857

DATE

11/18/22