



PATIENT

Marble Brito

PRESENTING CLINICAL SIGNS

Patient was presented due to first episode of seizures. Intermittent blindness on PE. Preventatives and vaccines UTD. Abnormal PE/Chem/CBC/UA Results: CBC --- unremarkable CHEM --- unremarkable NH3 --- normal

SPECIES

Feline

COMPUTED TOMOGRAPHY OF THE SKULL

A high resolution pre- and post-contrast CT study of the skull is provided for review.

BREED

DSH

COMPUTED TOMOGRAPHIC FINDINGS

The pictured parts of the dentition are complete and unremarkable in all jaw quadrants. The nasal cavity presents the expected aerated spaces between thin & even conchae and turbinates with smooth mucosal lining. Both temporomandibular joints present congruent joint spaces with even subchondral bone surfaces and are considered within normal limits. Both tympanic bullae are aerated, the mucosal lining is not seen, the bony wall is smooth and thin. The external ear canals are within normal limits.

SEX

SF

AGE

10 Months

INTERPRETED BY

Sebastian Schaub, DVM
Dr. med. vet. DipECVDI

The submandibular and medial retropharyngeal lymph nodes are small and elongated with a normal short-to-long-axis-ratio is < 0.5, the attenuation and contrast enhancement pattern is uniform.

HOSPITAL NAME

Veterinary Image Center

COMPUTED TOMOGRAPHIC DIAGNOSIS

- Intracranial possibly intraaxial lesion region of the left parietal lobe

REFERRING VET

Dr. L. Brito, DVM

INTERPRETATION OF THE FINDINGS & FURTHER RECOMMENDATIONS

There is an increased volume of the brain parenchyma in the region of the right parietal lobe can be caused by local edema - that can be inflammatory, ischemic or neoplastic in origin. If not done so yet, recommend complementing workup by a CSF tap is strongly recommended. As the CT study only presents a mass effect indicating an intraaxial lesion, MRI is warranted for further specification of potential underlying differentials.

INVOICE

55268

DATE

11-18-22



PATIENT

Marble Brito

SPECIES

Feline

BREED

DSH

SEX

SF

AGE

10 Months

INTERPRETED BY

Sebastian Schaub, DVM
Dr. med. vet. DipECVDI

HOSPITAL NAME

Veterinary Image
Center

REFERRING VET

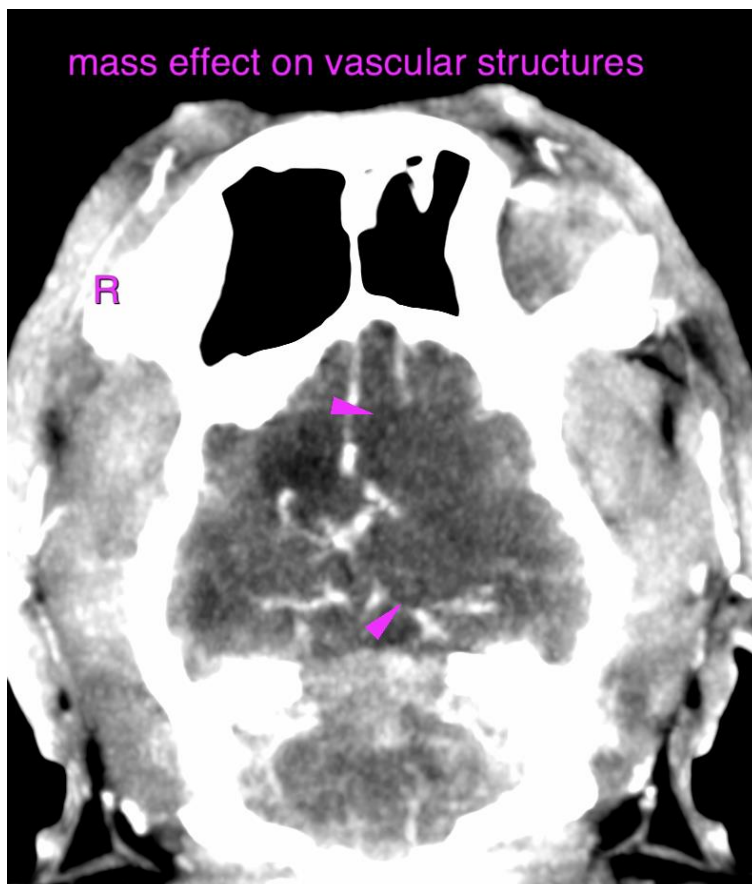
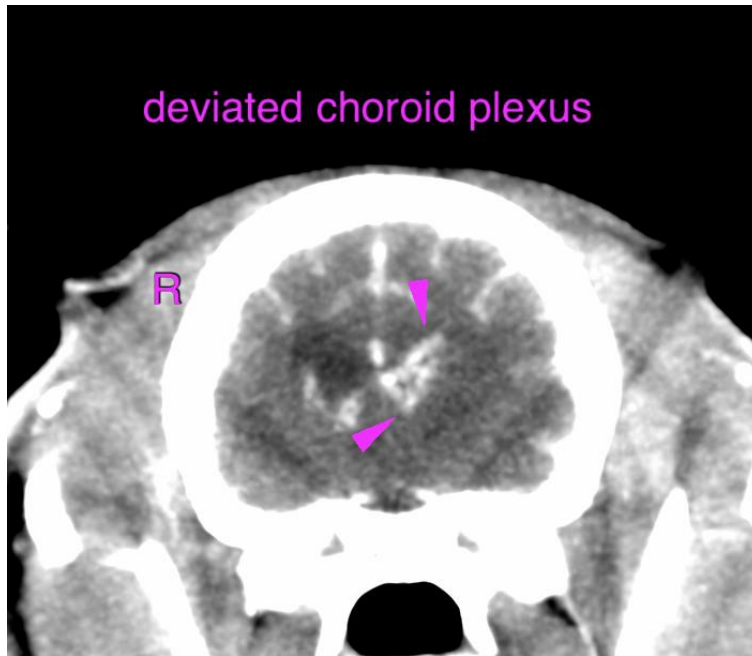
Dr. L. Brito, DVM

INVOICE

55268

DATE

11-18-22





PATIENT

Marble Brito

The information and recommendations provided are based on the images presented by the referring veterinarian/sonographer. No evaluation can be communicated regarding pathology that was not visible in the image/video clips provided.

SPECIES

Feline

Thank you for this referral. If the clinical or image interpretation does not parallel your findings or if I can be of any further assistance please contact me.

BREED

DSH

Sebastian Schaub, Sebastian Schaub, DVM, Dr. med. vet. DipECVDI
sebast.schaub@gmail.com

SEX

SF

AGE

10 Months

INTERPRETED BY

Sebastian Schaub, DVM
Dr. med. vet. DipECVDI

HOSPITAL NAME

Veterinary Image
Center

REFERRING VET

Dr. L. Brito, DVM

INVOICE

55268

DATE

11-18-22