



**PATIENT**

Addie Bach

**PRESENTING CLINICAL SIGNS**

Pet presented today for a dental cleaning

**SPECIES**

Canine

**COMPUTED TOMOGRAPHY OF THE SKULL**

A high resolution plain CT study of the skull is provided for review.

**BREED**

Australian Shepherd

**COMPUTED TOMOGRAPHIC FINDINGS**

Triadan 103, 108, 201, 208 are absent. A small remaining fragment of the root of triadan 201 is seen within the respective alveolar crest. Remaining fragments of the roots of triadan 108&208 are noted within the alveolar crests. Triadan 110 presents a moderate widening of the periodontal space. Mineralized material is attached to the crowns of the premolar and molar teeth A generalized

**SEX**

FS

The nasal cavity presents the expected aerated spaces between thin & even conchae and turbinates with smooth mucosal lining.

**AGE**

13 Years

Both temporomandibular joints present congruent joint spaces with even subchondral bone surfaces and are considered within normal limits.

Both tympanic bullae are aerated, the mucosal lining is not seen, the bony wall is smooth and thin. The external ear canals are within normal limits.

**COMPUTED TOMOGRAPHIC DIAGNOSIS**

**INTERPRETED BY**

Sebastian Schaub, DVM  
Dr. med. vet. DipECVDI

- Periodontal disease 110
- Dental tartar
- Remaining fragments of the roots of triadan 108, 201, and 208 without signs of infection
- Absent triadan 201, 103, 108, 201 and 208

**HOSPITAL NAME**

Cranberry Holistic  
Pet Care

**INTERPRETATION OF THE FINDINGS & FURTHER RECOMMENDATIONS**

The findings present evidence of generalized dental tartar and advanced periodontal disease of triadan 110. A complete dental workup has already been performed, regarding the history. The remaining roots of triadan 108, 201 and 208 are considered as an incidental finding, as there are no signs of infection.

**REFERRING VET**

Cynthia Maro

**INVOICE**

55267

**DATE**

11-18-22



**PATIENT**

Addie Bach

**SPECIES**

Canine

**BREED**

Australian Shepherd

**SEX**

FS

**AGE**

13 Years

**INTERPRETED BY**

Sebastian Schaub, DVM  
Dr. med. vet. DipECVDI

**HOSPITAL NAME**

Cranberry Holistic  
Pet Care

**REFERRING VET**

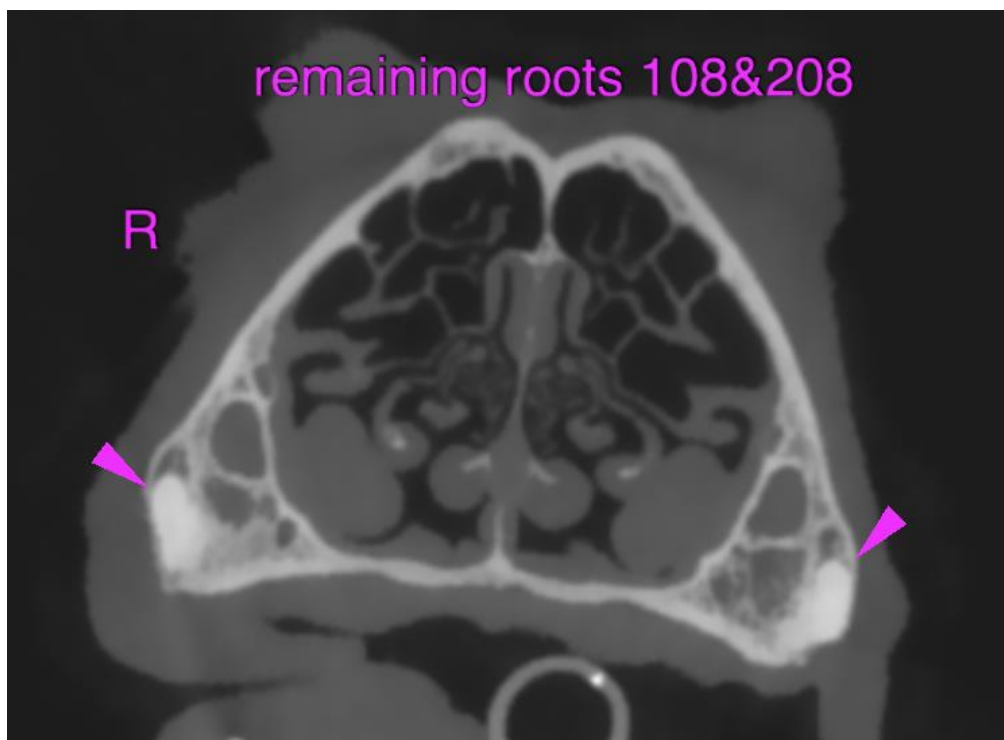
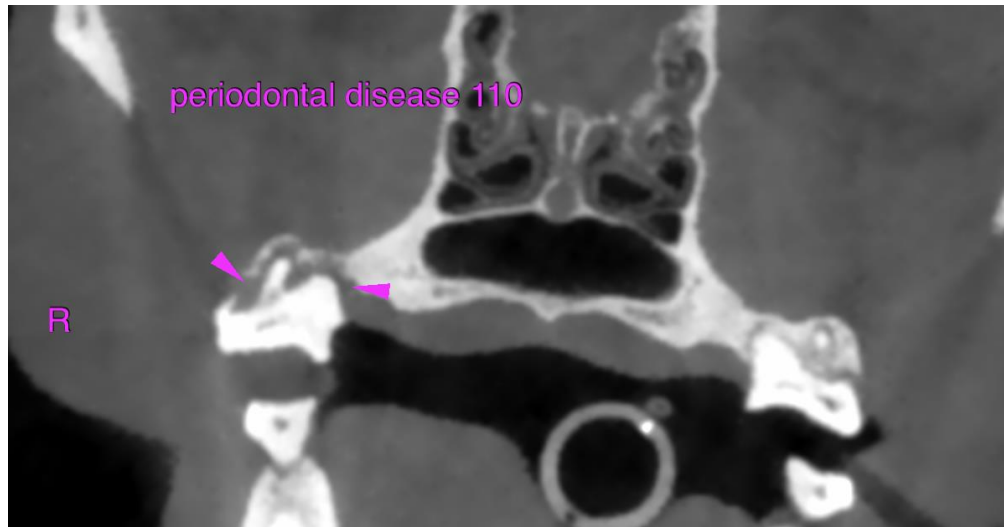
Cynthia Maro

**INVOICE**

55267

**DATE**

11-18-22





**PATIENT**

Addie Bach

The information and recommendations provided are based on the images presented by the referring veterinarian/sonographer. No evaluation can be communicated regarding pathology that was not visible in the image/video clips provided.

**SPECIES**

Canine

Thank you for this referral. If the clinical or image interpretation does not parallel your findings or if I can be of any further assistance please contact me.

**Sebastian Schaub**, Sebastian Schaub, DVM, Dr. med. vet. DipECVDI  
sebast.schaub@gmail.com

**BREED**

Australian Shepherd

**SEX**

FS

**AGE**

13 Years

**INTERPRETED BY**

Sebastian Schaub, DVM  
Dr. med. vet. DipECVDI

**HOSPITAL NAME**

Cranberry Holistic  
Pet Care

**REFERRING VET**

Cynthia Maro

**INVOICE**

55267

**DATE**

11-18-22