



PATIENT

Zeus Penney

SPECIES

Feline

BREED

DSH

SEX

Male

AGE

6M

WEIGHT

3

INTERPRETED BY

Sebastian Schaub, DVM
Dr. med. vet.
DipECVDI

IMAGING PERFORMED BY

Ana

HOSPITAL NAME

Animal Trust - Bolton

REFERRING VET

Ana Valega

INVOICE

72632

DATE

11-17-25

PRESENTING CLINICAL SIGNS

2nd opinion- Chronic sneezing with epistaxis constantly sneezing +++ with red discharge, has nose bleeds, every time P sneezes, lots of discharge, dark and bloody in colour, sneezes many times per day had cat flu when O got him - OR bloody discharge coming eyes at that time as well Been in owners possession since june - from website - house in marple where all cats where outside in garden- did report 'breeder' but unsure if anything came of it, lots of litters mixed together with diff ages, paid a lot of money for P, not vac or chipped tx at last vets with ns aids and abx (synulox and zodon- zodon had bad SE) utd with vaccines, is chipped now occ lethargic, not as much energy as should for kitten, will play and then flop down - exercise intolerance will struggle to breathe and audible DUDE wnl has another female cat 2m older than him- she had cat flu but recovered well better on ns aids, no real change on abx All swabs came back negative

COMPUTED TOMOGRAPHY OF THE SKULL & NECK

A high resolution pre- and post-contrast CT study of the skull and neck is provided for review.

COMPUTED TOMOGRAPHIC FINDINGS

Triadan 106, 206 and 303 are absent.

In the rostral segment of the left nasal cavity, advanced destruction of the nasal conchal structures is appreciated. The left nasal opening is distorted in comparison to the right nostril.

Both temporomandibular joints present congruent joint spaces with even subchondral bone surfaces and are considered within normal limits.

Both tympanic bullae are aerated, the mucosal lining is not seen, the bony wall is smooth and thin. The external ear canals are within normal limits.

The brain presents no deviation from normal anatomy and symmetry. The brain parenchyma is homogeneous and within normal limits for attenuation and distribution of contrast enhancement. The ventricular system is non-dilated and symmetric.

The submandibular and medial retropharyngeal lymph nodes are moderately prominent.

COMPUTED TOMOGRAPHIC DIAGNOSIS

- Focal destructive rhinitis left nasal cavity
- Soft tissue material in left nasal opening
- Lymphadenopathy mandibular and medial retropharyngeal lymph nodes bilaterally - compatible with reactive lymphoid hyperplasia

INTERPRETATION OF THE FINDINGS & FURTHER RECOMMENDATIONS

The localized destructive rhinitis in the left nasal cavity can be either primary infectious in origin - common primary viral ± bacterial or less likely mycotic superinfection - or due to the unilateral changes can be indicative for foreign body related rhinitis.

The distorted left nasal opening is considered as a sequela to exudate, however a small nasal mass needs to be ruled out as well.

If not done so yet, complementing workup by rhinoscopy would be ideal.



PATIENT

Zeus Penney

SPECIES

Feline

BREED

DSH

SEX

Male

AGE

6M

WEIGHT

3

INTERPRETED BY

Sebastian Schaub, DVM
Dr. med. vet.
DipECVDI

IMAGING PERFORMED BY

Ana

HOSPITAL NAME

Animal Trust - Bolton

REFERRING VET

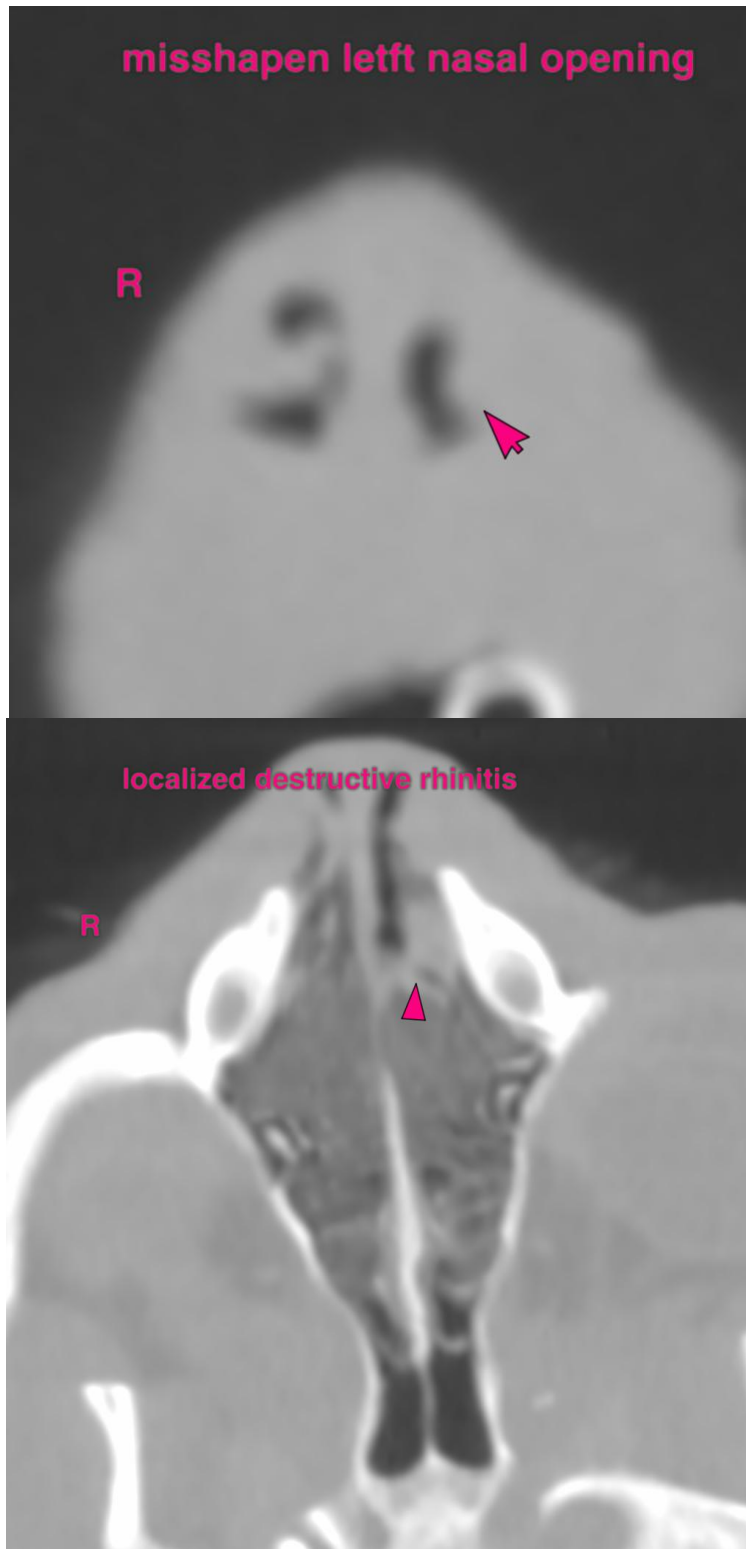
Ana Valega

INVOICE

72632

DATE

11-17-25





PATIENT

Zeus Penney

The information and recommendations provided are based on the images presented by the referring veterinarian/sonographer. No evaluation can be communicated regarding pathology that was not visible in the image/video clips provided.

SPECIES

Feline

Thank you for this referral. If the clinical or image interpretation does not parallel your findings or if I can be of any further assistance please contact me.

BREED

DSH

Sebastian Schaub, Sebastian Schaub, DVM, Dr. med. vet. DipECVDI

info@sonopath.com

SEX

Male

AGE

6M

WEIGHT

3

INTERPRETED BY

Sebastian Schaub, DVM
Dr. med. vet.
DipECVDI

IMAGING PERFORMED BY

Ana

HOSPITAL NAME

Animal Trust - Bolton

REFERRING VET

Ana Valega

INVOICE

72632

DATE

11-17-25