



PATIENT

Charley Parks

SPECIES

Canine

BREED

Terrier X

SEX

FS

AGE

13Y, 10M

WEIGHT

16.2kg

INTERPRETED BY

Sebastian Schaub, DVM
Dr. med. vet.
DipECVDI

IMAGING PERFORMED BY

Janice

HOSPITAL NAME

Bridgwater Veterinary
Hospital and Wellness
Centre

REFERRING VET

Dr. Cristina Prade
Ramos

INVOICE

72648

DATE

11-17-25

PRESENTING CLINICAL SIGNS

Abdominal mass (spleen vs liver, marked enlarged), elevated liver enzymes, circumanal gland tumour (right perianal) and non-regenerative anemia

Abnormal PE/Chem/CBC/JA Results: Increased plt 534 K/uL, alt 585 U/L, alkp 608 U/L, Na 171 mmol/L

COMPUTED TOMOGRAPHY OF THE THORAX AND ABDOMEN

A high resolution pre- and post-contrast CT study of the thorax and abdomen is provided for review.

COMPUTED TOMOGRAPHIC FINDINGS

Thorax

Level with the intervertebral disc space C6/C7, mild peripheral mineralized disc material is protruding into the vertebral canal, occupying approximately 5% of the cross-sectional area of the vertebral canal at the same level. The vertebral endplates T4/T5 and T12/T13 present mild spondylosis formation.

The sternal, cranial mediastinal and tracheobronchial lymph nodes are small elongated with a normal short-to-long-axis-ratio is < 0.5, the attenuation and contrast enhancement pattern is uniform and considered within normal limits.

The cardiovascular structures including the pulmonary vasculature are within normal limits.

The bronchial tree presents with regular branching and tapers uniformly towards the periphery as expected, the bronchial walls are thin and smooth. The bronchus-to-artery ratio is within normal limits.

The left lung presents a generalized decreased volume with zones of dystelectasis of the lung – a mediastinal shift of the left is appreciated. The remainder of the lung parenchyma presents the expected architecture and attenuation behavior

Small incidental gas pockets are seen within the esophageal lumen; there is no evidence of abnormal dilation.

Abdomen

Both kidneys present within normal limits for size, shape and organ architecture. After contrast administration, a bilaterally symmetric and uniform nephro- and pyelogram is noted.

Nodular enlargement of the adrenal gland bilaterally is seen, presenting a heterogenous contrast enhancement pattern; measuring up to 18 mm in diameter.

Both liver and spleen present with normal shape, even surface, uniformly attenuating parenchyma and homogeneous contrast enhancement, unremarkable.

Protruding from the caudoventral margin of the left medial liver lobe, an irregular roundish, pedunculated soft tissue attenuating mass with interspersed irregular mineralization and a heterogeneous contrast enhancement pattern is seen; measuring 11 x 8 x 10 cm. The peritoneal fat surrounding the left divisional hepatic mass presents mild soft tissue striation. The stomach is mildly deviated dorsally by the mass effect.

The pancreas is evenly contoured; the pancreatic parenchyma is homogeneous and presents uniform contrast enhancement.

The position, delineation, wall and content of the gastrointestinal tract are considered within normal limits throughout.



PATIENT

Charley Parks

SPECIES

Canine

BREED

Terrier X

SEX

FS

AGE

13Y, 10M

WEIGHT

16.2kg

INTERPRETED BY

Sebastian Schaub, DVM
Dr. med. vet.
DipECVDI

IMAGING PERFORMED BY

Janice

HOSPITAL NAME

Bridgwater Veterinary
Hospital and Wellness
Centre

REFERRING VET

Dr. Cristina Prade
Ramos

INVOICE

72648

DATE

11-17-25

At the lateral aspect of the right anal sac an ovoid shaped, uniform soft tissue attenuating and mild irregular contrast enhancing mass is seen; measuring 3.1 x 2.0 x 4.8 cm. The right perianal mass is in contact with the ipsilateral anal sac.

The hypogastric lymph nodes are small and unremarkable.

Level with the intervertebral disc spaces T12/T13 to L2/L3, disc material is protruding into the vertebral canal, occupying approximately $\leq 20\%$ of the cross-sectional area of the vertebral canal at the same level – the dural tube is mildly distorted.

COMPUTED TOMOGRAPHIC DIAGNOSIS

- Pedunculated hepatic soft tissue mass left medial liver lobe with dystrophic mineralization and mild surrounding peritonitis
- Right perianal soft tissue mass – likely unrelated to the right anal sac, fitting history of circumanal gland tumor
- Nodular enlargement adrenal gland bilaterally without vascular invasion
- Intervertebral disc herniation C6/C7 and T12/T13 to L2/L3 with possible dynamic myelocompression
- Spondylosis deformans
- No evidence of pulmonary metastatic disease

INTERPRETATION OF THE FINDINGS & FURTHER RECOMMENDATIONS

The hepatic soft tissue mass is consistent with primary hepatic neoplasia and hepatocellular carcinoma is likely. Complete surgical excision of the hepatic mass is considered feasible.

The nodular enlargement of the adrenal glands can present benign (non)functional adrenal nodular hyperplasia or neoplastic transformation (e.g. adenoma, adenocarcinoma). Testing of the pituitary adrenal axis can be considered as advanced diagnostic test.



PATIENT

Charley Parks

SPECIES

Canine

BREED

Terrier X

SEX

FS

AGE

13Y, 10M

WEIGHT

16.2kg

INTERPRETED BY

Sebastian Schaub, DVM
Dr. med. vet.
DipECVDI

IMAGING PERFORMED BY

Janice

HOSPITAL NAME

Bridgwater Veterinary
Hospital and Wellness
Centre

REFERRING VET

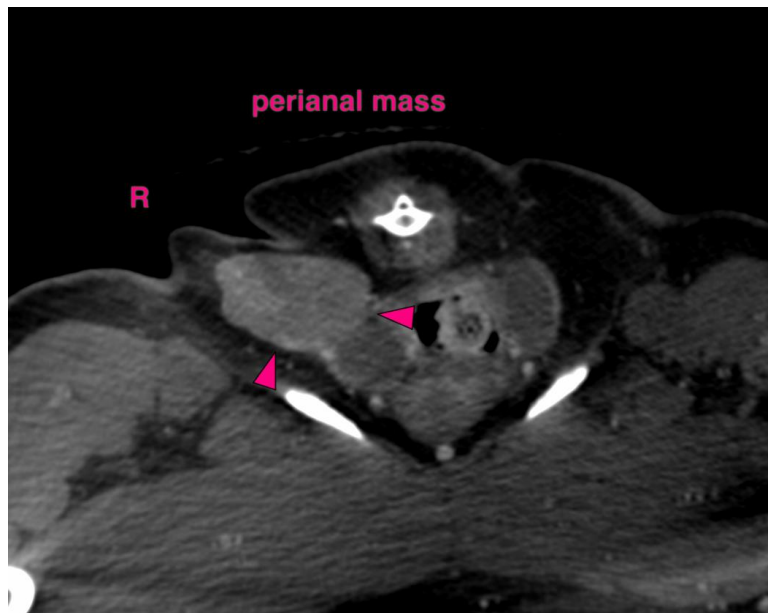
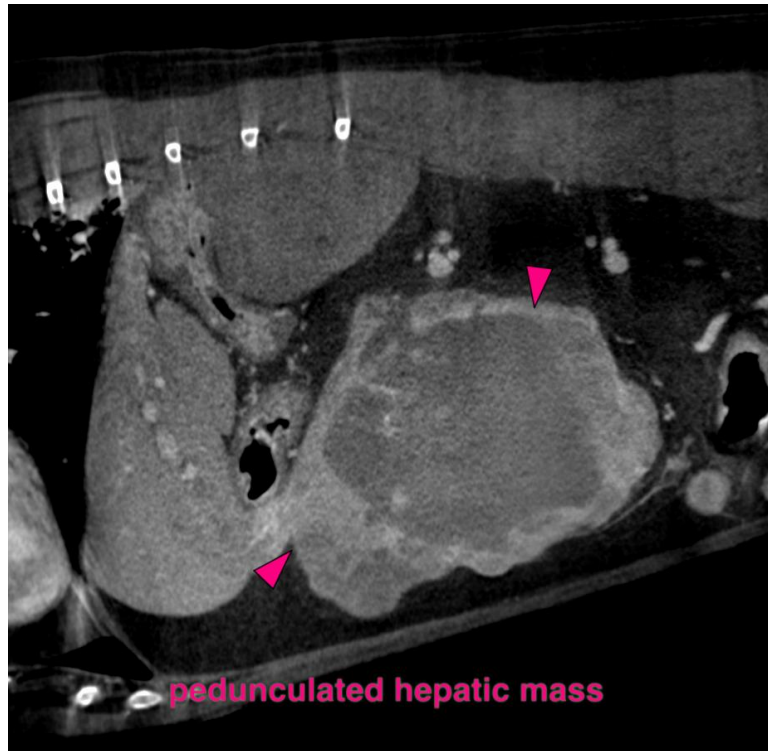
Dr. Cristina Prade
Ramos

INVOICE

72648

DATE

11-17-25





PATIENT

Charley Parks

SPECIES

Canine

BREED

Terrier X

SEX

FS

AGE

13Y, 10M

WEIGHT

16.2kg

INTERPRETED BY

Sebastian Schaub, DVM
Dr. med. vet.
DipECVDI

IMAGING PERFORMED BY

Janice

HOSPITAL NAME

Bridgwater Veterinary
Hospital and Wellness
Centre

REFERRING VET

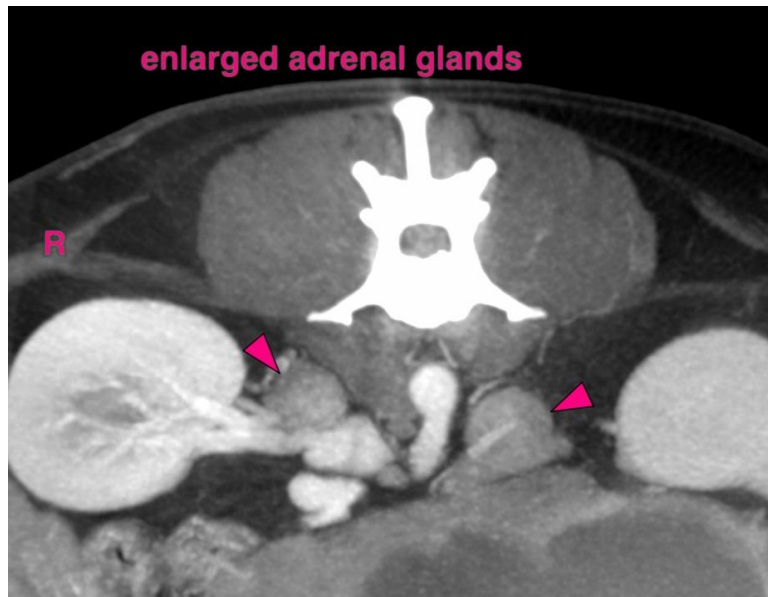
Dr. Cristina Prade
Ramos

INVOICE

72648

DATE

11-17-25



The information and recommendations provided are based on the images presented by the referring veterinarian/sonographer. No evaluation can be communicated regarding pathology that was not visible in the image/video clips provided.

Thank you for this referral. If the clinical or image interpretation does not parallel your findings or if I can be of any further assistance please contact me.

Sebastian Schaub, Sebastian Schaub, DVM, Dr. med. vet. DipECVDI
info@sonopath.com