



PATIENT

Lollie Michaels

PRESENTING CLINICAL SIGNS

Coughing at night, restless hx of anal gland adenocarcinoma removed 2 years ago
Abnormal PE/Chem/CBC/UA Results: Pending

SPECIES

Canine

RADIOGRAPHIC STUDY OF THE THORAX & ABDOMEN

A right lateral projection of the thorax and abdomen is provided for review.

BREED

Mixed

RADIOGRAPHIC FINDINGS

Thorax

Multifocal moderate spondylosis formation is present along the thoracic spine. The costal cartilages present moderate degenerative changes.

SEX

Female / sp

The extrathoracic soft tissues present homogeneous without abnormalities.

The heart is of normal size and shape, there is no evidence of cardiac chamber or vascular enlargement. The pulmonary vasculature is within normal limits.

AGE

12 Years

The trachea is normal in diameter and presents the anticipated course. The luminal outline of the trachea is smooth.

INTERPRETED BY

Sebastian Schaub, DVM
Dr. med. vet. DipECVDI

The bronchial tree presents with thin walls and tapers uniformly towards the periphery as expected.

The lung parenchyma presents the expected architecture and generalized mild increased radiopacity due to and unstructured reticular lung pattern; the intrapulmonary vascular branching is seen up to the third order lung vessels.

HOSPITAL NAME

New Bridge
Veterinary Practice

The diaphragm is well delineated with even surface and the expected mild cranial bulging of the diaphragmatic cupola.

Abdomen

REFERRING VET

Dr. Abina Glennon

Generalized bridging spondylosis formation is seen along the lumbar spine. The facet joints along the cranial lumbar spine present moderate osteophyte new bone formation.

No abnormalities of the extraabdominal soft tissues are noted. The abdominal wall is smooth and thin.

INVOICE

48402

The serosal detail is maintained throughout the peritoneal and retroperitoneal space.

The hepatic volume is mildly increased and the caudoventral margins are rounded.

DATE

11-16-21

The splenic body and tail are considered normal for position, size, shape and opacity.

Both kidneys are seen and present with normal size, shape, delineation and opacity. The urinary bladder is in its anticipated position. No radiopaque calculi are noted throughout the upper and lower urinary tract.

**PATIENT**

The stomach presents normal content.

Lollie Michaels

The small intestinal loops are of even diameter and non-dilated, a small amount of gas is seen within the small intestinal loops and considered within normal limits.

SPECIES

The colon is seen in the expected position and presents with appropriate content.

Canine

RADIOGRAPHIC DIAGNOSIS**BREED**

Mixed

- Unstructured interstitial lung pattern
- Mild hepatomegaly
- Spondylosis deformans
- Serial spondylarthrosis
- Moderate degenerative changes costal cartilages
- No evidence of sublumbar lymphadenopathy

SEX

Female / sp

INTERPRETATION OF THE FINDINGS & FURTHER RECOMMENDATIONS

The unstructured interstitial lung pattern is likely a sequela to age related changes of the lung parenchyma. However, given the history of cough, mild (allergic ,eosinophilic) pneumonitis is a potential as well, the odds for infectious disease are considered low. There is no evidence of pulmonary metastatic disease.

AGE

12 Years

Potentials for the hepatomegaly include metabolic hepatic disease/steroid induced hepatopathy, hepatitis or neoplastic infiltration. Ultrasound including FNA sampling can be used as minimally advanced diagnostic tests.

INTERPRETED BY

Sebastian Schaub, DVM
Dr. med. vet. DipECVDI

HOSPITAL NAME

New Bridge
Veterinary Practice

REFERRING VET

Dr. Abina Glennon

INVOICE

48402

DATE

11-16-21



PATIENT

Lollie Michaels

SPECIES

Canine

BREED

Mixed

SEX

Female / sp

AGE

12 Years

INTERPRETED BY

Sebastian Schaub, DVM
Dr. med. vet. DipECVDI

HOSPITAL NAME

New Bridge
Veterinary Practice

REFERRING VET

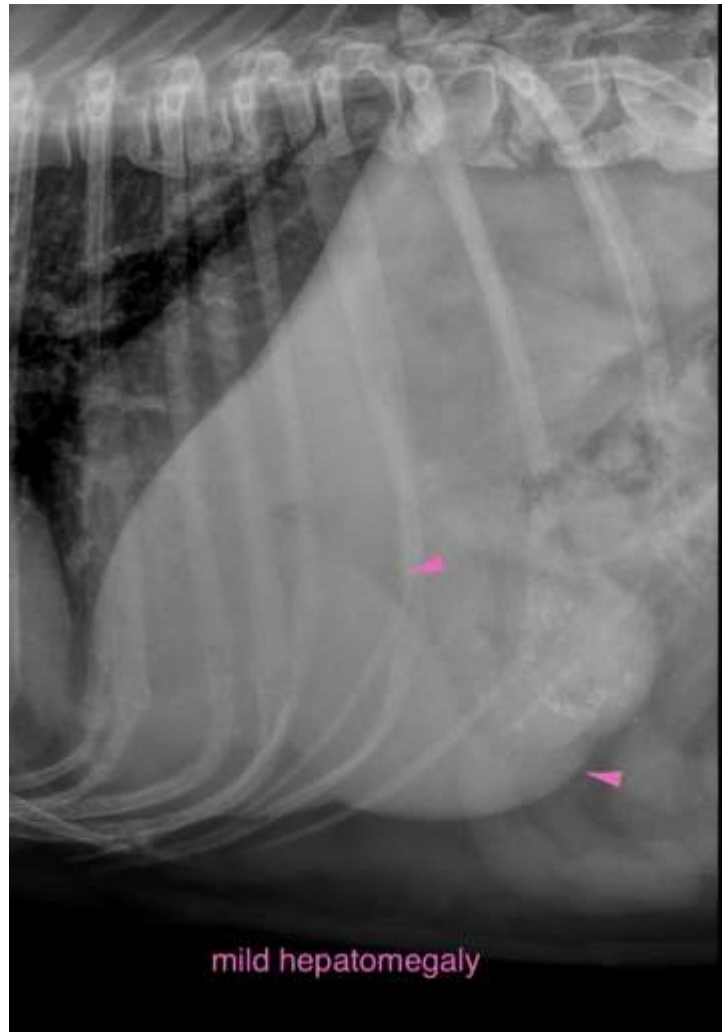
Dr. Abina Glennon

INVOICE

48402

DATE

11-16-21



The information and recommendations provided are based on the images presented by the referring veterinarian. No evaluation can be communicated regarding pathology that was not visible in the image/video clips provided.

Thank you for this referral. If the clinical or image interpretation does not parallel your findings or if I can be of any further assistance please contact me.

Sebastian Schaub, Sebastian Schaub, DVM, Dr. med. vet. DipECVDI
sebast.schaub@gmail.com