



PATIENT

Lily Hernandez

SPECIES

Canine

BREED

Maltese

SEX

Female

AGE

22 Months

WEIGHT

8

INTERPRETED BY

Sebastian Schaub, DVM
Dr. med. vet. DipECVDI

IMAGING PERFORMED BY

Armando Sobrado

HOSPITAL NAME

Miami Springs Animal
Hospital

REFERRING VET

Dr. Perez

INVOICE

12282

DATE

11/15/25

PRESENTING CLINICAL SIGNS

The pet has 14 vomits in 12 hours.

COMPUTED TOMOGRAPHIC STUDY OF THE ABDOMEN

A high resolution pre- and post-contrast CT study of the abdomen is provided for review.

COMPUTED TOMOGRAPHIC FINDINGS

The serosal fat presents normal attenuation behavior. There is no evidence of peritoneal effusion or peritonitis.

A separate right & left caudal vena cava of the pre-renal segment is seen.

Both kidneys present within normal limits for size, shape and organ architecture. After contrast administration a bilaterally symmetric and uniform nephro- and pyelogram is noted.

The adrenal glands are within normal limits for size, shape and organ architecture.

Both liver and spleen present with normal shape, even surface, uniformly attenuating parenchyma and homogeneous contrast enhancement, unremarkable.

At the medial aspect of the cranial extremity of the spleen, two well-defined, soft tissue attenuating nodules, presenting the same attenuation and contrast enhancement pattern like the spleen is seen; measuring 6 mm and 15 mm respectively.

The pancreas is evenly contoured, the pancreatic parenchyma is homogeneous and presents uniform contrast enhancement.

The stomach contains a small volume of fluid attenuating material. The position, delineation, wall and content of the gastrointestinal tract are considered within normal limits throughout. The colon contains a small amount of partially hyperattenuating fecal material.

The bony and surrounding soft tissue structures reveal no abnormalities.

COMPUTED TOMOGRAPHIC DIAGNOSIS

- Mild fluid pattern stomach
- Splenunculus
- Double caudal vena cava

INTERPRETATION OF THE FINDINGS & FURTHER RECOMMENDATIONS

There is no evidence of foreign material, abnormal gas pattern or signs for gastrointestinal mechanical obstruction. Rule out gastroenteritis, dysbacteriosis, parasitic infection, dietary indiscretion, pancreatitis, other.



PATIENT

Lily Hernandez

SPECIES

Canine

BREED

Maltese

SEX

Female

AGE

22 Months

WEIGHT

8

INTERPRETED BY

Sebastian Schaub, DVM
Dr. med. vet. DipECVDI

IMAGING PERFORMED BY

Armando Sobrado

HOSPITAL NAME

Miami Springs Animal
Hospital

REFERRING VET

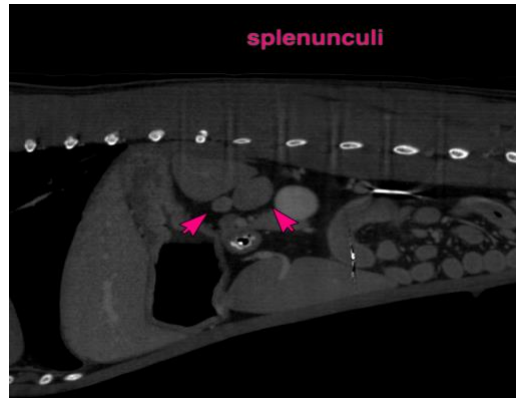
Dr. Perez

INVOICE

12282

DATE

11/15/25



The information and recommendations provided are based on the images presented by the referring veterinarian/sonographer. No evaluation can be communicated regarding pathology that was not visible in the image/video clips provided.

Thank you for this referral. If the clinical or image interpretation does not parallel your findings or if I can be of any further assistance please contact me.

Sebastian Schaub, DVM, Dr. med. vet. DipECVDI
info@sonopath.com