



PATIENT PRESENTING CLINICAL SIGNS

Ollie Campbell Cough began acutely in September. No other symptoms.
Abnormal PE/Chem/CBC/UA Results: see rads

SPECIES RADIOGRAPHIC STUDY OF THE THORAX

Canine Radiographs of the thorax in two orthogonal imaging planes are provided for review.

RADIOGRAPHIC FINDINGS

BREED The surrounding bony structures are within normal limits.

BREED Puggle The extrathoracic soft tissues present homogeneous without abnormalities.

SEX The trachea presents a J-shaped bending level with the base of the heart and a faint convex shaped soft tissue opacity is superimposed on the caudal tracheal segment. In the VD projection the trachea makes a moderate right sided bend.

SEX MN

There is no evidence of cardiac chamber or vascular enlargement. The pulmonary vasculature is within normal limits.

AGE

12 Years The cranial mediastinum presents the expected soft tissue opacity. The mediastinal width is less than twice the width of the vertebral column at the same level.

INTERPRETED BY

Sebastian Schaub, DVM
Dr. med. vet. DipECVDI

The bronchial tree presents with thin walls and tapers uniformly towards the periphery as expected.

The lung parenchyma presents the expected architecture and opacity; the intrapulmonary vascular branching is seen up to the third order lung vessels.

HOSPITAL NAME

Louise Mandeville

The diaphragm is well delineated with even surface and the expected mild cranial bulging of the diaphragmatic cupola.

RADIOGRAPHIC DIAGNOSIS

- Suspect heart base mass

REFERRING VET

Dr. Louise Mandeville

INTERPRETATION OF THE FINDINGS & FURTHER RECOMMENDATIONS

INVOICE

48377

The radiographic study is highly concerning for heart base mass and heart base tumor such as paraganglioma is likely in brachycephalic dogs. Recommend cardiac echo to confirm the diagnosis.

No additional abnormalities are noted, explaining the cough.

DATE

11-15-21



PATIENT

Ollie Campbell

SPECIES

Canine

BREED

Puggle

SEX

MN

AGE

12 Years

INTERPRETED BY

Sebastian Schaub, DVM
Dr. med. vet. DipECVDI

HOSPITAL NAME

Louise Mandeville

REFERRING VET

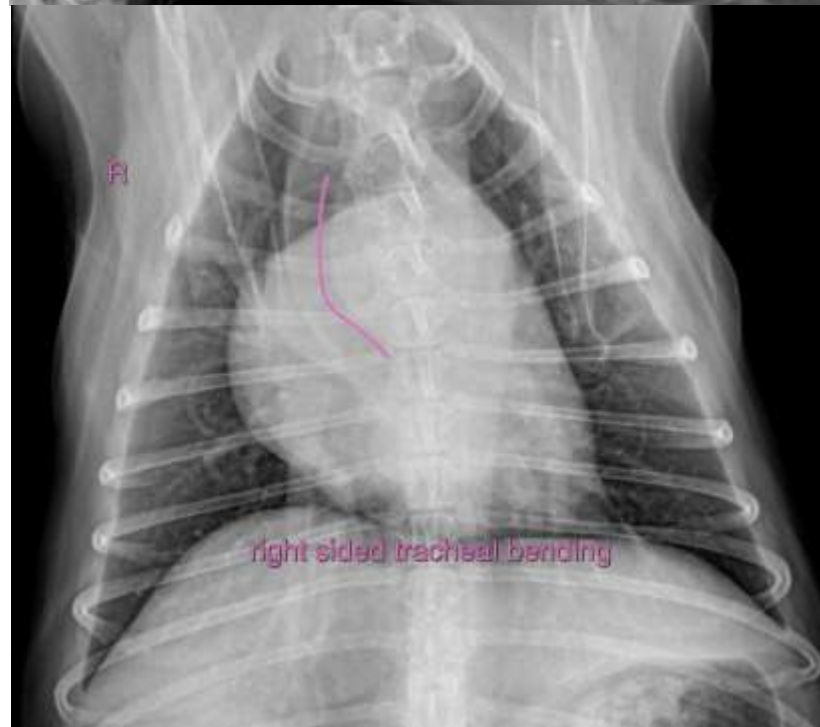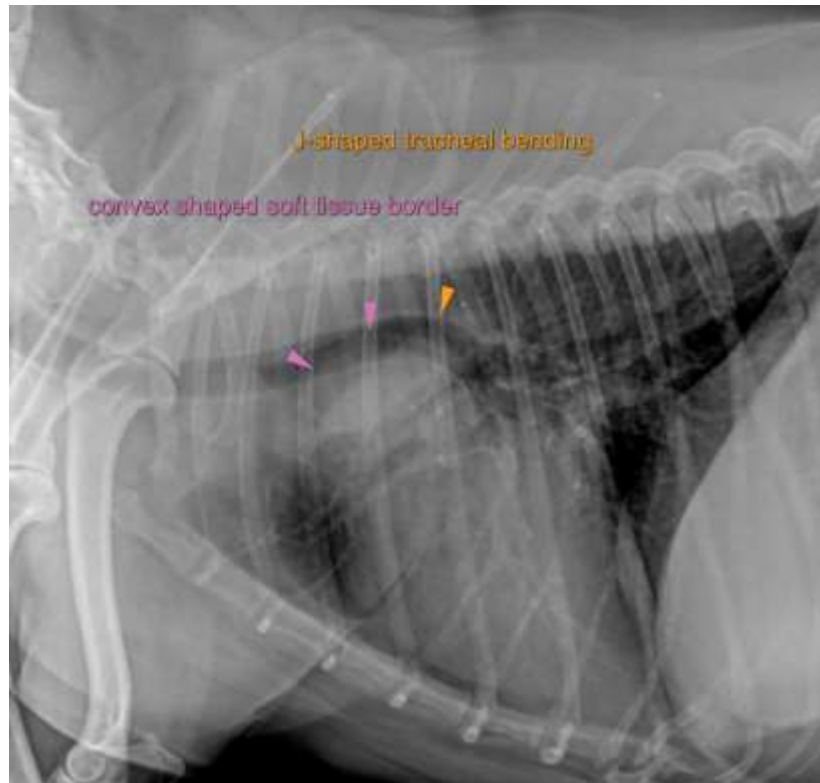Dr. Louise Mandeville

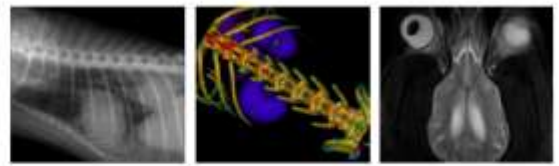
INVOICE

48377

DATE

11-15-21





PATIENT

Ollie Campbell

SPECIES

Canine

The information and recommendations provided are based on the images presented by the referring veterinarian. No evaluation can be communicated regarding pathology that was not visible in the image/video clips provided.

BREED

Puggle

Thank you for this referral. If the clinical or image interpretation does not parallel your findings or if I can be of any further assistance please contact me.

Sebastian Schaub, Sebastian Schaub, DVM, Dr. med. vet. DipECVDI
sebast.schaub@gmail.com

SEX

MN

AGE

12 Years

INTERPRETED BY

Sebastian Schaub, DVM
Dr. med. vet. DipECVDI

HOSPITAL NAME

Louise Mandeville

REFERRING VET

Dr. Louise Mandeville

INVOICE

48377

DATE

11-15-21