



PATIENT

Biscotti Sharifan

SPECIES

Feline

BREED

DSH

SEX

Sayed Female

AGE

4 Years

WEIGHT

5

INTERPRETED BY

Sebastian Schaub, DVM
Dr. med. vet. DipECVDI

IMAGING PERFORMED BY

Sabrina Lowder

HOSPITAL NAME

Mountain West VS

REFERRING VET

Dr. Naomi Guzman

INVOICE

35532

DATE

11/14/25

PRESENTING CLINICAL SIGNS

History of a dental cleaning performed a week ago and was doing great 3 days post dental. Is now not wanting to eat and acting like her jaw or mouth may be painful.

Abnormal PE/Chem/CBC/UA Results: BW is WNL

COMPUTED TOMOGRAPHIC STUDY OF THE SKULL

A high resolution pre- and post-contrast CT study of the skull is provided for review.

COMPUTED TOMOGRAPHIC FINDINGS

The pictured parts of the dentition are complete and unremarkable in all jaw quadrants.

In both nasal cavities, a small amount of fluid attenuating material is attached to a mild to moderately thickened mucosal lining.

Both temporomandibular joints present congruent joint spaces with even subchondral bone surfaces and are considered within normal limits.

Both tympanic bullae are aerated, the mucosal lining is not seen, the bony wall is smooth and thin. The external ear canals are within normal limits.

The brain presents no deviation from normal anatomy and symmetry. The brain parenchyma is homogeneous and within normal limits for attenuation and distribution of contrast enhancement. The ventricular system is non-dilated and symmetric.

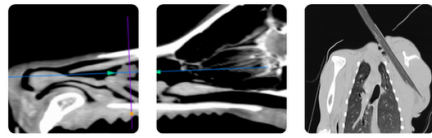
The submandibular and medial retropharyngeal lymph nodes are small and elongated with a normal short-to-long-axis-ratio is < 0.5 , the attenuation and contrast enhancement pattern is uniform.

COMPUTED TOMOGRAPHIC DIAGNOSIS

- Mild rhinitis

INTERPRETATION OF THE FINDINGS & FURTHER RECOMMENDATIONS

The CT study of the skull reveals no specific abnormalities, but signs of mild rhinitis – rule out early stage of viral infection as cause for the inappetence.



PATIENT

Biscotti Sharifan

SPECIES

Feline

BREED

DSH

SEX

Sayed Female

AGE

4 Years

WEIGHT

5

INTERPRETED BY

Sebastian Schaub, DVM
Dr. med. vet. DipECVDI

IMAGING PERFORMED BY

Sabrina Lowder

HOSPITAL NAME

Mountain West VS

REFERRING VET

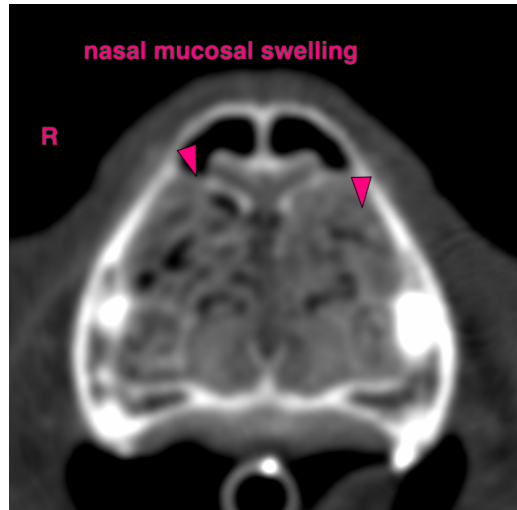
Dr. Naomi Guzman

INVOICE

35532

DATE

11/14/25



The information and recommendations provided are based on the images presented by the referring veterinarian/sonographer. No evaluation can be communicated regarding pathology that was not visible in the image/video clips provided.

Thank you for this referral. If the clinical or image interpretation does not parallel your findings or if I can be of any further assistance please contact me.

Sebastian Schaub, DVM, Dr. med. vet. DipECVDI
info@sonopath.com