SonoPath Teleradiology

EDUCATIONAL TELECONSULTATION SERVICES™

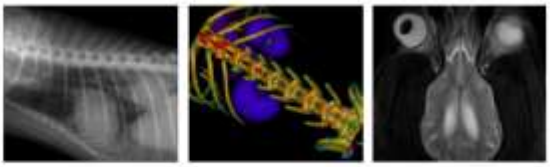

SonoPath.com
1-800-838-4268 info@sonopath.com

PATIENT

Andy Knipe

SPECIES

Canine

BREED

Mixed

SEX

Neutered Male

AGE

13 Years

INTERPRETED BY

Sebastian Schaub, DVM
Dr. med. vet. DipECVDI

HOSPITAL NAME

Neel Veterinary Hospital

REFERRING VET

Dr. Sheri Hodgson

INVOICE

48328

DATE

11-14-21

PRESENTING CLINICAL SIGNS

O states back in Aug. pt had 4 seizures within the course of 24hrs. Blue Pearl kept pt at the time and no further seizures noted. No MRI performed. O states pt has not had a seizures until early October. O states this morning about 3a pt had a seizure and legs moving and loss control of bowels. O states pt has now had a total of about 14 seizures today. O states about 9:15a seizures became more frequent with one occurring about every 5 minutes. O states pt is not on any regular meds. O states pt does have a benign tumor in pt mouth that rDVM debulks about 4-5 months. O states rDVM will also inject liquid nitrogen in between each debulking.

COMPUTED TOMOGRAPHY OF THE SKULL

A high resolution pre- and post-contrast CT study of the skull is provided for review.

COMPUTED TOMOGRAPHIC FINDINGS

Triadan 402&403 are absent. There is a cauliflower like, mild expansile osteoproliferative mass originating from the rostral segment of the right mandible measuring approximately 2.6 cm in diameter. The mass causes mesial deviation of triadan 401 and distal deviation of triadan 301. There is evidence of remodeling of the left ramus of the mandible level with the symphysis. Post contrast administration the expansile osseous mass of the right mandible presents mild contrast enhancement. The mass is extending distally within the medullary cavity of the right body of the mandible up to the level of triadan 406/407.

The nasal cavity presents the expected aerated spaces between thin & even conchae and turbinates with smooth mucosal lining.

Both temporomandibular joints present congruent joint spaces with even subchondral bone surfaces and are considered within normal limits.

Both tympanic bullae are aerated, the mucosal lining is not seen, the bony wall is smooth and thin; multiple small tympanic bone spicules are protruding from the septum of the tympanic bulla into the lumen. The external ear canals are within normal limits.

Post contrast administration, in the rostral fossa cranii, centered on the falx cerebri, an irregular marginated, plaque like mass is visible perforating the left ventral aspect of the cribriform plate. There is a mass effect on the brain parenchyma at the same level with a mild midline shift to the right. The mass in the rostral fossa cranii is measuring approximately 1.5 x 1.3 x 2.5 cm in size.

The submandibular and medial retropharyngeal lymph nodes are small and elongated with a normal short-to-long-axis-ratio is < 0.5, the attenuation and contrast enhancement pattern is uniform.

COMPUTED TOMOGRAPHIC DIAGNOSIS

- Intracranial likely extraaxial plaque like mass rostral fossa cranii
- Monostotic aggressive osteoproliferative mass rostral segment right body of mandible
- Absent triadan 402&403

SonoPath Teleradiology

EDUCATIONAL TELECONSULTATION SERVICES™

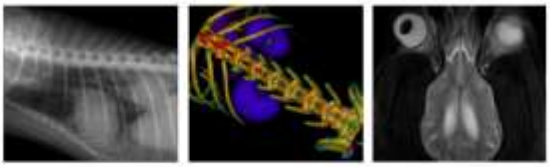

SonoPath.com
1-800-838-4268 info@sonopath.com

PATIENT

Andy Knipe

SPECIES

Canine

BREED

Mixed

SEX

Neutered Male

AGE

13 Years

INTERPRETED BY

Sebastian Schaub, DVM
Dr. med. vet. DipECVDI

HOSPITAL NAME

Neel Veterinary Hospital

REFERRING VET

Dr. Sheri Hodgson

INVOICE

48328

DATE

11-14-21

INTERPRETATION OF THE FINDINGS & FURTHER RECOMMENDATIONS

There is an intracranial likely extraaxial mass in the left rostral fossa cranii and neoplasia such as meningioma, granular cell tumor, round cell neoplasia, other are potentials here. The finding explains the clinical signs. Complementing workup by a CSF tap appears beneficial. The chances of radiation therapy might be discussed with oncologist.

The mineralizing mass of the right mandible is highly suggestive for primary osseous neoplasia, such as osteosarcoma, (multilobulated) osteochondrosarcoma, chondrosarcoma, squamous cell carcinoma, other. FNA sampling/biopsy can be used as advanced diagnostic tests if applicable.

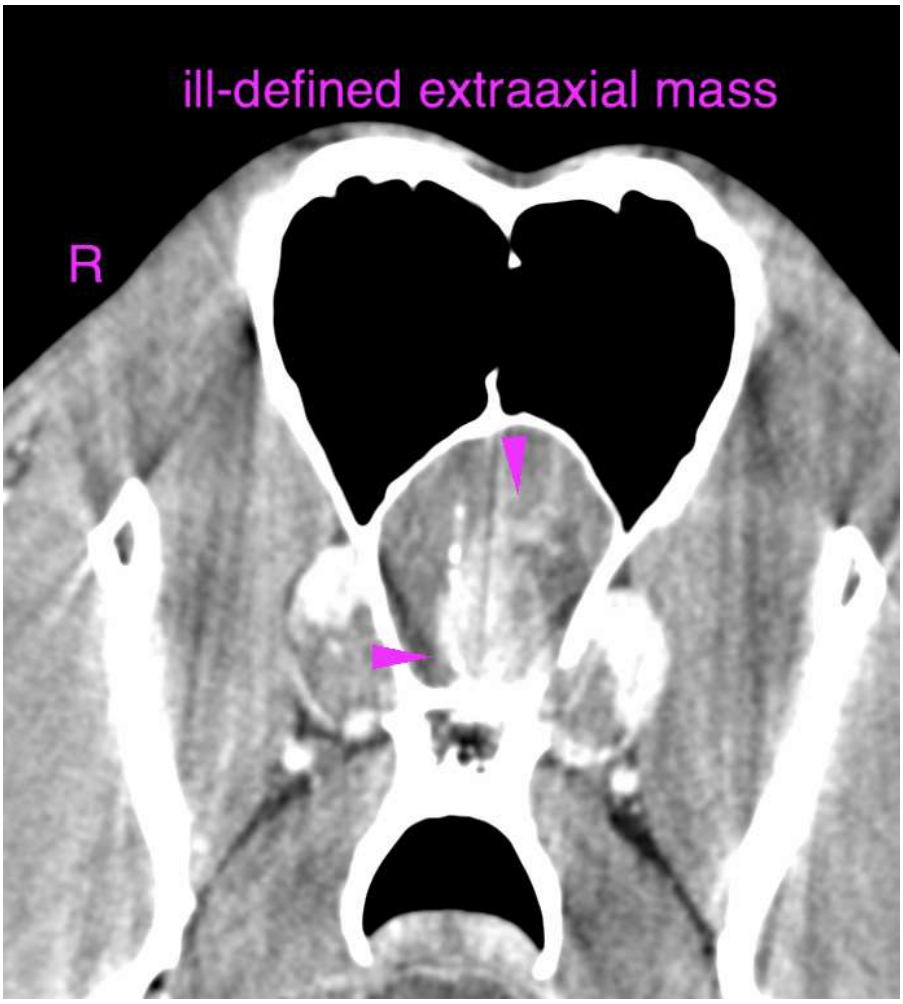

SonoPath Teleradiology

EDUCATIONAL TELECONSULTATION SERVICES™

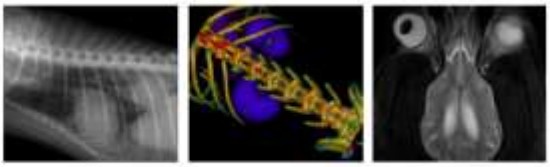

SonoPath.com
1-800-838-4268 info@sonopath.com

PATIENT

Andy Knipe

SPECIES

Canine

BREED

Mixed

SEX

Neutered Male

AGE

13 Years

INTERPRETED BY

Sebastian Schaub, DVM
Dr. med. vet. DipECVDI

HOSPITAL NAME

Neel Veterinary Hospital

REFERRING VET

Dr. Sheri Hodgson

INVOICE

48328

DATE

11-14-21

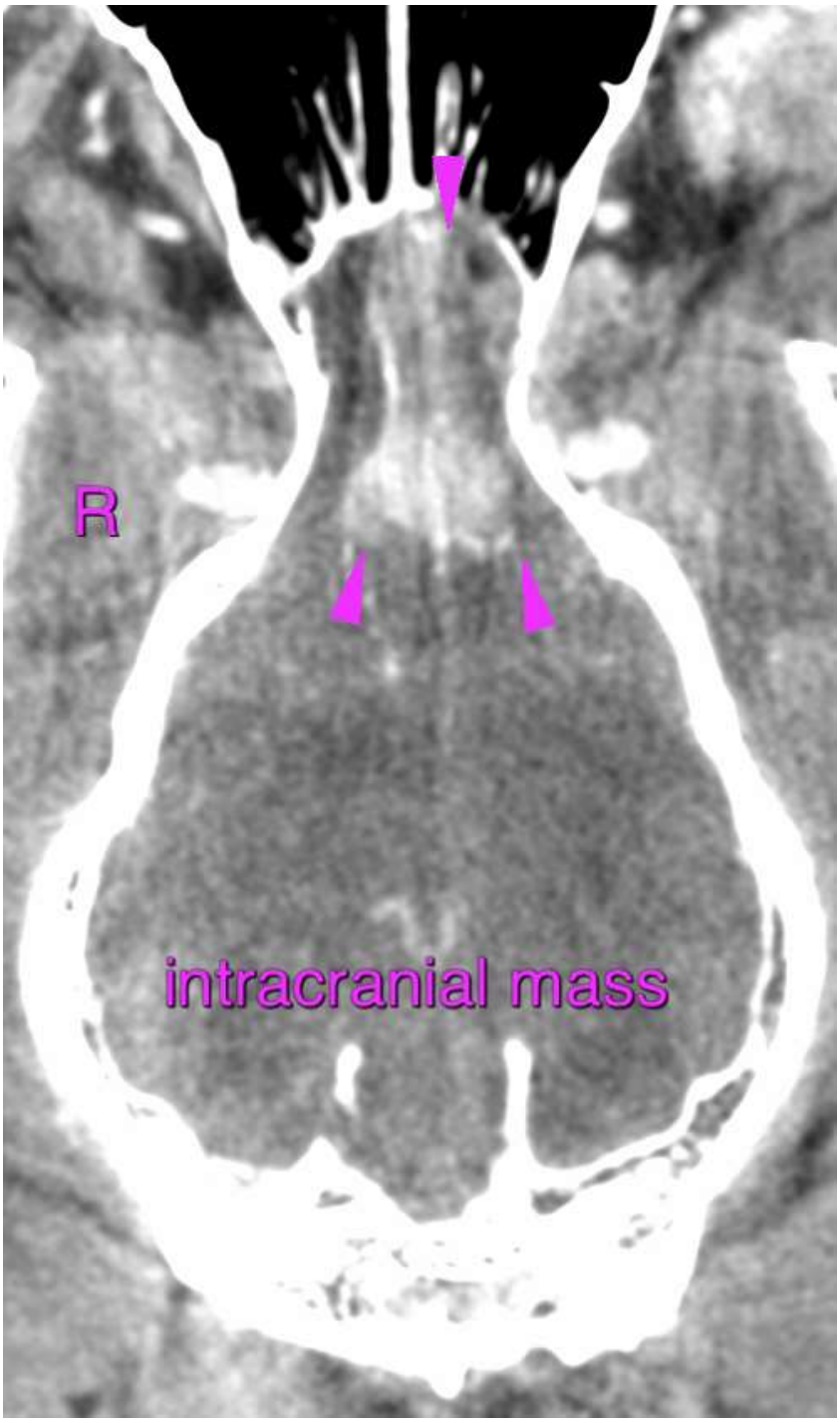

SonoPath Teleradiology

EDUCATIONAL TELECONSULTATION SERVICES™

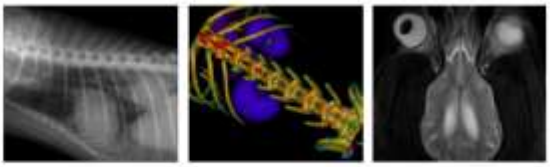

SonoPath.com
1-800-838-4268 info@sonopath.com

PATIENT

Andy Knipe

SPECIES

Canine

BREED

Mixed

SEX

Neutered Male

AGE

13 Years

INTERPRETED BY

Sebastian Schaub, DVM
Dr. med. vet. DipECVDI

HOSPITAL NAME

Neel Veterinary Hospital

REFERRING VET

Dr. Sheri Hodgson

INVOICE

48328

DATE

11-14-21

SonoPath Teleradiology

EDUCATIONAL TELECONSULTATION SERVICES™

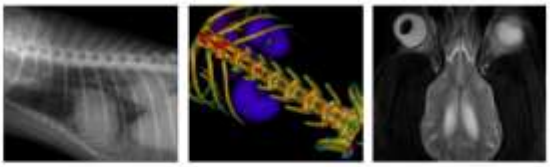

SonoPath.com
1-800-838-4268 info@sonopath.com

PATIENT

Andy Knipe

SPECIES

Canine

BREED

Mixed

SEX

Neutered Male

AGE

13 Years

INTERPRETED BY

Sebastian Schaub, DVM
Dr. med. vet. DipECVDI

HOSPITAL NAME

Neel Veterinary Hospital

REFERRING VET

Dr. Sheri Hodgson

INVOICE

48328

DATE

11-14-21

The information and recommendations provided are based on the images presented by the referring veterinarian. No evaluation can be communicated regarding pathology that was not visible in the image/video clips provided.

Thank you for this referral. If the clinical or image interpretation does not parallel your findings or if I can be of any further assistance please contact me.

Sebastian Schaub, Sebastian Schaub, DVM, Dr. med. vet. DipECVDI
sebast.schaub@gmail.com