



## PATIENT

Wilbur Forbes

## SPECIES

Canine

## BREED

English Bulldog

## SEX

MN

## AGE

6Y, 5M, 20D

## WEIGHT

32kg

## INTERPRETED BY

Sebastian Schaub, DVM  
Dr. med. vet.  
DipECVDI

## IMAGING PERFORMED BY

Byrony Tomic-Beard,  
BS, CVT

## HOSPITAL NAME

Westford Veterinary  
Emergency and  
Referral Center

## REFERRING VET

Mallory Watson, DVM

## INVOICE

72625

## DATE

11-13-25

## PRESENTING CLINICAL SIGNS

Reason for presentation: CT skull/thorax + oral mass biopsy Presenting History: Mass on left side of mouth--first noted as facial/eye swelling Mid-September History/notes from rDVM records: Firm golf ball sized swelling at the left zygomatic arch with extension into gingiva Urgent Concern: facial swelling on left

Abnormal PE/Chem/CBC/UA Results: 11/7/25: CBC/Chem/T4: CBC: Platelets 499 (120-412), Retic Hemoglobin 28.7 (23.8-28.3); all else WNL Chem: TP 7.7 (5.5-7.5), Globulin 4.5 (2.4-4); all else WNL T4: 2.7 (1-4)

## COMPUTED TOMOGRAPHY OF THE SKULL & THORAX

A high resolution pre- and post-contrast CT study of the skull and a post-contrast CT study of the thorax are provided for review.

## COMPUTED TOMOGRAPHIC FINDINGS

### Skull

The skull has a brachycephalic conformation with significant crowding and rotation of the maxillary premolar teeth.

Multiple teeth are absent.

Centered on the rostral half of the left zygomatic arch, a roundish, granular mineralizing mass is seen – protruding into the subcutaneous tissue and lateral aspect of the left orbital cavity. The mineralizing mass of the left zygomatic arch is measuring approximately 7.0 x 5.2 x 7.6 cm. The associated left zygomatic bone and alveolar process of the left maxillary bone present advanced aggressive osteolysis. The left ocular bulb is deviated rostrolaterally by the mass effect.

The nasal cavity presents the expected aerated spaces between thin & even conchae and turbinates with smooth mucosal lining.

Both temporomandibular joints present congruent joint spaces with even subchondral bone surfaces and are considered within normal limits.

Both tympanic bullae are aerated, the mucosal lining is not seen, the bony wall is smooth and thin. The horizontal segment of the ear canals is moderately narrowed. Both external ear canals present mild to moderate shell-like mineralization.

The brain presents no deviation from normal anatomy and symmetry. The brain parenchyma is homogeneous and within normal limits for attenuation and distribution of contrast enhancement. The ventricular system is non-dilated and symmetric.

The left medial retropharyngeal lymph node is prominent.

The right mandibular salivary gland is absent.

### Thorax

Along the thoracic spine multifocal variable degree of congenital malformation of the vertebra along with spondylosis formation is seen.

The sternal, cranial mediastinal and tracheobronchial lymph nodes are small elongated with a normal short-to-long-axis-ratio is < 0.5, the attenuation and contrast enhancement pattern is uniform and considered within normal limits.



## PATIENT

Wilbur Forbes

## SPECIES

Canine

## BREED

English Bulldog

## SEX

MN

## AGE

6Y, 5M, 20D

## WEIGHT

32kg

## INTERPRETED BY

Sebastian Schaub, DVM  
Dr. med. vet.  
DipECVDI

## IMAGING PERFORMED BY

Byrony Tomic-Beard,  
BS, CVT

## HOSPITAL NAME

Westford Veterinary  
Emergency and  
Referral Center

## REFERRING VET

Mallory Watson, DVM

## INVOICE

72625

## DATE

11-13-25

The cardiovascular structures including the pulmonary vasculature are within normal limits.

The bronchial tree presents with regular branching and tapers uniformly towards the periphery as expected, the bronchial walls are thin and smooth. The bronchus-to-artery ratio is within normal limits.

The lung parenchyma presents the expected architecture and attenuation behavior.

Small incidental gas pockets are seen within the esophageal lumen; there is no evidence of abnormal dilation.

## COMPUTED TOMOGRAPHIC DIAGNOSIS

- Polyostotic aggressive mixed osteoproliferative and osteolytic mass left zygomatic arch
- Secondary left sided exophthalmos
- Lymphadenopathy left medial retropharyngeal lymph node
- Suspect history of sialoadenectomy right mandibular salivary gland, less likely agenesis
- Multiple absent teeth
- Multiple hemivertebra thoracic spine
- Spondylosis deformans
- No evidence of pulmonary metastatic disease

## INTERPRETATION OF THE FINDINGS & FURTHER RECOMMENDATIONS

The clinically appreciated mass at the left aspect of the skull is caused by primary osseous neoplasia – differentials include multilobular osteochondrosarcoma, osteosarcoma, chondrosarcoma. Biopsy of the mass can be performed for specification. If surgical management is considered – caudal maxillectomy with the rostral osteotomy line being located mesial to triadan 206 is warranted.

The prominent left medial retropharyngeal lymph node is equivocal for reactive lymphoid hyperplasia versus metastatic spread.



## PATIENT

Wilbur Forbes

## SPECIES

Canine

## BREED

English Bulldog

## SEX

MN

## AGE

6Y, 5M, 20D

## WEIGHT

32kg

## INTERPRETED BY

Sebastian Schaub, DVM  
Dr. med. vet.  
DipECVDI

## IMAGING PERFORMED BY

Byrony Tomic-Beard,  
BS, CVT

## HOSPITAL NAME

Westford Veterinary  
Emergency and  
Referral Center

## REFERRING VET

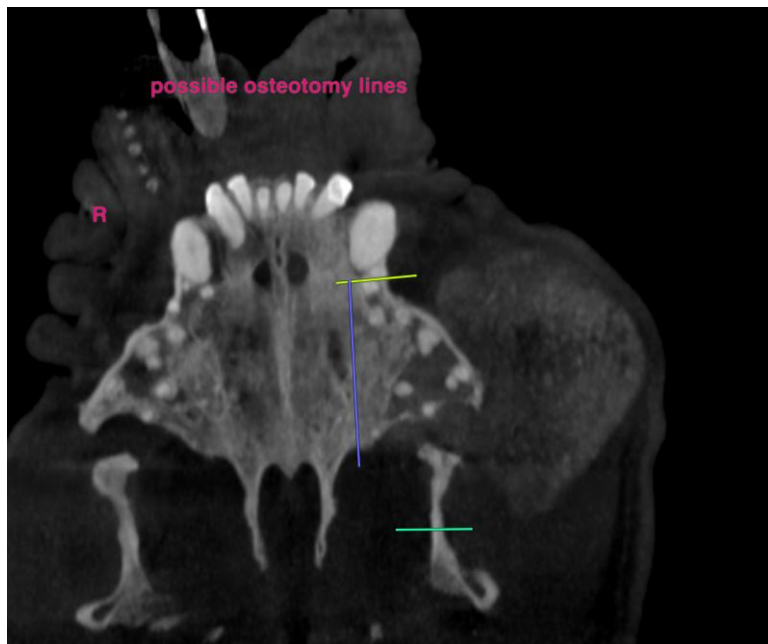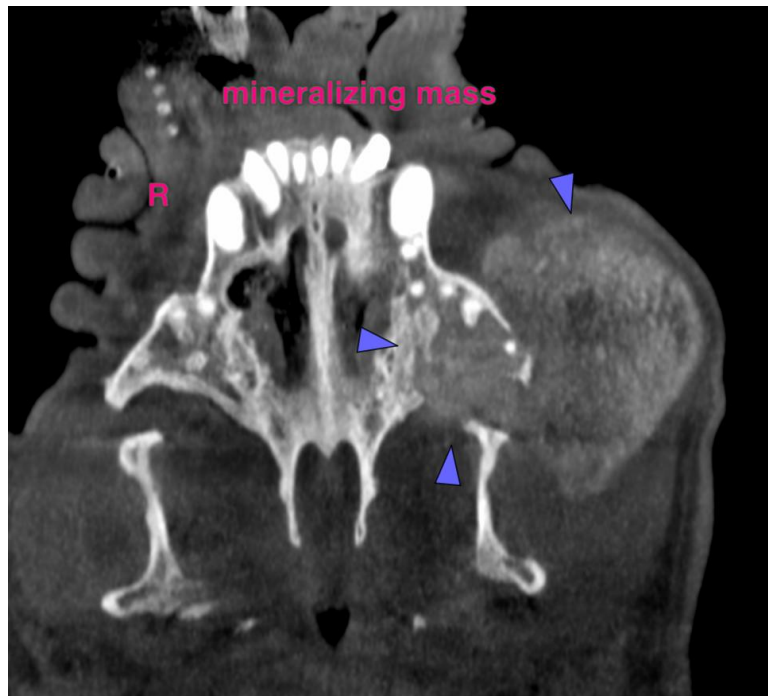Mallory Watson, DVM

## INVOICE

72625

## DATE

11-13-25





## PATIENT

Wilbur Forbes

## SPECIES

Canine

## BREED

English Bulldog

## SEX

MN

## AGE

6Y, 5M, 20D

## WEIGHT

32kg

## INTERPRETED BY

Sebastian Schaub, DVM  
Dr. med. vet.  
DipECVDI

## IMAGING PERFORMED BY

Byrony Tomic-Beard,  
BS, CVT

## HOSPITAL NAME

Westford Veterinary  
Emergency and  
Referral Center

## REFERRING VET

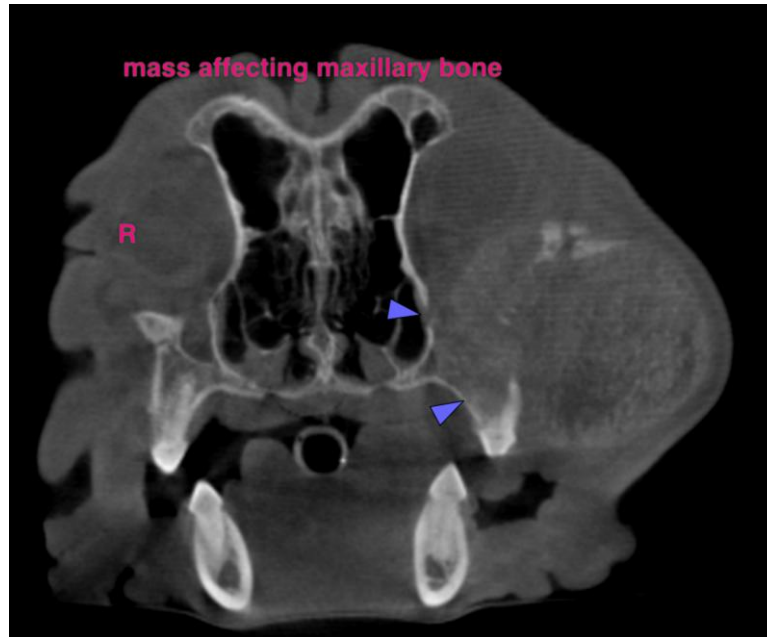
Mallory Watson, DVM

## INVOICE

72625

## DATE

11-13-25



The information and recommendations provided are based on the images presented by the referring veterinarian/sonographer. No evaluation can be communicated regarding pathology that was not visible in the image/video clips provided.

Thank you for this referral. If the clinical or image interpretation does not parallel your findings or if I can be of any further assistance please contact me.

**Sebastian Schaub**, Sebastian Schaub, DVM, Dr. med. vet. DipECVDI  
[info@sonopath.com](mailto:info@sonopath.com)