



PATIENT

Sylvie Jarit

SPECIES

Canine

BREED

Shetland Sheepdog

SEX

Female

AGE

2Y

WEIGHT

20lbs

INTERPRETED BY

Sebastian Schaub, DVM
Dr. med. vet.
DipECVDI

IMAGING PERFORMED BY

GC/JA

HOSPITAL NAME

The Pet Hospital of
Stratford

REFERRING VET

Dr. Robert Bashkin

INVOICE

72616

DATE

11-13-25

PRESENTING CLINICAL SIGNS

Puppy check! Mom says that she should be due in the next 24 hours.

RADIOGRAPHIC STUDY OF THE ABDOMEN

Radiographs of the abdomen in two orthogonal image planes are provided for review.

RADIOGRAPHIC FINDINGS

Major parts of the ventral abdomen are occupied by the enlarged uterus, counting 5 fetuses.

The intestinal tract is displaced cranially and dorsally by the mass effect.

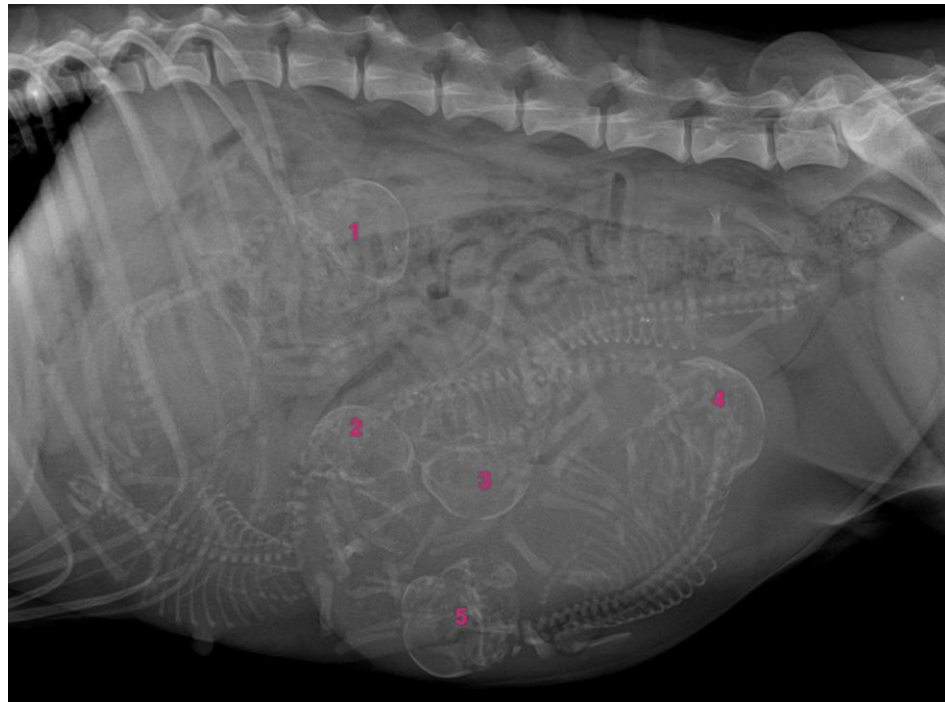
No abnormalities are appreciated throughout the remainder of the abdomen.

RADIOGRAPHIC DIAGNOSIS

- Gravid uterus

INTERPRETATION OF THE FINDINGS & FURTHER RECOMMENDATIONS

I can appreciate five fetal skulls and spines in the current set of radiographs.





PATIENT

Sylvie Jarit

The information and recommendations provided are based on the images presented by the referring veterinarian/sonographer. No evaluation can be communicated regarding pathology that was not visible in the image/video clips provided.

SPECIES

Canine

Thank you for this referral. If the clinical or image interpretation does not parallel your findings or if I can be of any further assistance please contact me.

BREED

Shetland Sheepdog

Sebastian Schaub, Sebastian Schaub, DVM, Dr. med. vet. DipECVDI
info@sonopath.com

SEX

Female

AGE

2Y

WEIGHT

20lbs

INTERPRETED BY

Sebastian Schaub, DVM
Dr. med. vet.
DipECVDI

**IMAGING
PERFORMED BY**

GC/JA

HOSPITAL NAME

The Pet Hospital of
Stratford

REFERRING VET

Dr. Robert Bashkin

INVOICE

72616

DATE

11-13-25