



**PATIENT**

Poa Trefren

**PRESENTING CLINICAL SIGNS**

Had mastocytoma diagnosed via report from Amazon diagnostics. Was seen and got abdominal ultrasound liver and splenic aspirates done. Multiple nodules on liver and spleen. Spleen slides sent to idexx sample did not have enough cellularity to determine further information at this time. Liver slides were sent with owner to take to oncology

**SPECIES**

Canine

**COMPUTED TOMOGRAPHY OF THE ABDOMEN**

A high resolution post contrast CT study of the abdomen is provided for review.

**BREED**

Border Collie

**COMPUTED TOMOGRAPHIC FINDINGS**

The most ventral aspects of the abdomen are cropped by the field of view.

**SEX**

The serosal fat presents normal attenuation behavior. There is no evidence of peritoneal effusion or peritonitis.

MN

Both kidneys present within normal limits for size, shape and organ architecture, a bilaterally symmetric and uniform nephrogram is noted.

**AGE**

9

The adrenal glands are within normal limits for size, shape and organ architecture.

**INTERPRETED BY**

Sebastian Schaub, DVM  
Dr. med. vet. DipECVDI

The pictured parts of the spleen present with normal shape, even surface, uniformly contrast enhancement, unremarkable.

The hepatic volume is moderately increased, and the liver is protruding caudally beyond the costal arch, the caudoventral margins are rounded.

**HOSPITAL NAME**

Wilvet Salem

The position, delineation, wall and content of the gastrointestinal tract are considered within normal limits throughout.

The vertebral endplates L1/L2 present mild spondylosis formation. Multiple gas inclusions are seen in the subcutaneous tissue along the caudal thoracic wall – suspect due to preceding subcutaneous injection.

**REFERRING VET**

Dr. Crystal Ebert

**COMPUTED TOMOGRAPHIC DIAGNOSIS**

- Hepatomegaly
- Mild spondylosis deformans

**INVOICE**

48346

**INTERPRETATION OF THE FINDINGS & FURTHER RECOMMENDATIONS**

Potentials for the hepatomegaly include metabolic hepatic disease, hepatitis or diffuse neoplastic infiltration. Repeating the FNA sampling or complementing workup by TruCut biopsy might be considered to rule in/out metastatic spread completely.

**DATE**

11-13-21

No abnormalities of the spleen are appreciated.



**PATIENT**

Poa Trefren

**SPECIES**

Canine

**BREED**

Border Collie

**SEX**

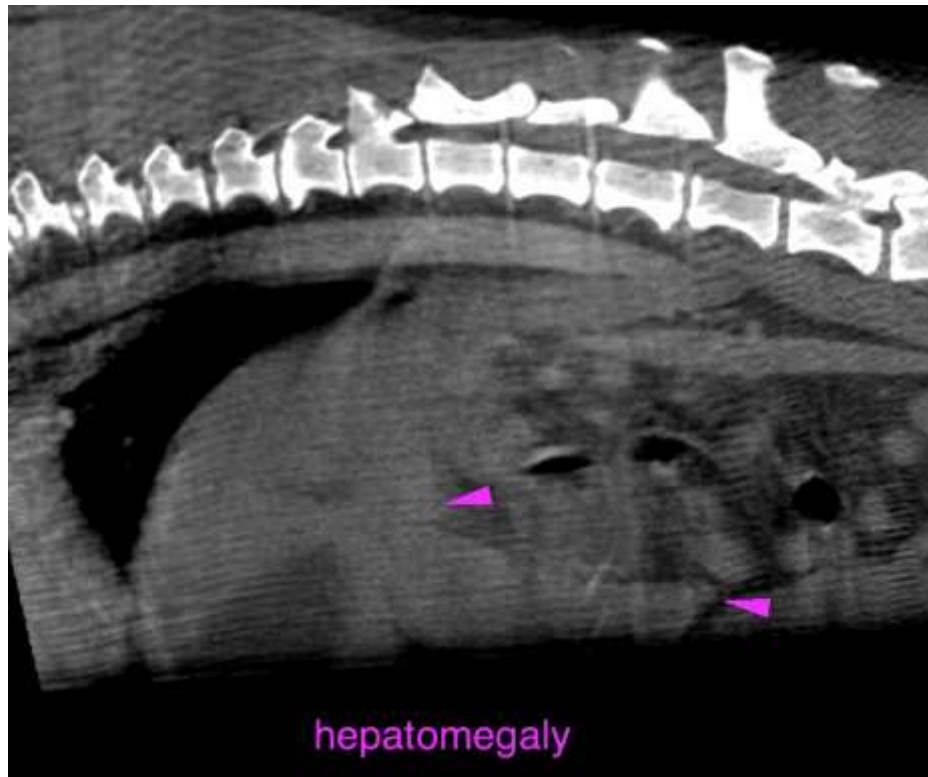
MN

**AGE**

9

**INTERPRETED BY**

Sebastian Schaub, DVM  
Dr. med. vet. DipECVDI



**HOSPITAL NAME**

Wilvet Salem

**REFERRING VET**

Dr. Crystal Ebert

**INVOICE**

48346

**DATE**

11-13-21

The information and recommendations provided are based on the images presented by the referring veterinarian. No evaluation can be communicated regarding pathology that was not visible in the image/video clips provided.

Thank you for this referral. If the clinical or image interpretation does not parallel your findings or if I can be of any further assistance please contact me.

**Sebastian Schaub**, Sebastian Schaub, DVM, Dr. med. vet. DipECVDI  
sebast.schaub@gmail.com