

**PATIENT**

Gigi Otaegui

PRESENTING CLINICAL SIGNS

intermittent respiratory distress. Followed by normal breathing. NSF on echo no hm

SPECIES

Canine

RADIOGRAPHIC STUDY OF THE THORAX

Radiographs of the thorax in three imaging planes are provided for review.

BREED

Yorkshire Terrier

The surrounding bony structures are within normal limits.

The extrathoracic soft tissues present homogeneous without abnormalities.

SEX

SF

The heart is of normal size and shape, there is no evidence of cardiac chamber or vascular enlargement. The pulmonary vasculature is within normal limits.

The cranial mediastinum presents the expected soft tissue opacity. The mediastinal width is less than twice the width of the vertebral column at the same level.

AGE

4 Years, 10 Months

In the right lateral projection including the caudal aspect of the neck, the pictured parts of the cervical tracheal segment presents a moderate reduced height.

INTERPRETED BYSebastian Schaub, DVM
Dr. med. vet. DipECVDI

The bronchial tree presents with thin walls and tapers uniformly towards the periphery as expected.

The lung parenchyma presents the expected architecture and opacity; the intrapulmonary vascular branching is seen up to the third order lung vessels.

The diaphragm is well delineated with even surface and the expected mild cranial bulging of the diaphragmatic cupola.

HOSPITAL NAMERockaway Animal
Hospital**RADIOGRAPHIC DIAGNOSIS**

- Suspect tracheal collapse cervical segment

REFERRING VET

Dr. Maniar

INTERPRETATION OF THE FINDINGS & FURTHER RECOMMENDATIONS

The findings are concerning for tracheal collapse, depending on the grade tracheal collapse can be source for respiratory distress. Radiographs of the neck might be considered during in- and expiration to confirm the finding. Tracheoscopy can be used alternatively and will allow further grading of tracheal collapse if present.

INVOICE

48337

The remainder of the thorax present without abnormal findings.

DATE

11-13-21



PATIENT

Gigi Otaegui

SPECIES

Canine

BREED

Yorkshire Terrier

SEX

SF

AGE

4 Years, 10 Months

INTERPRETED BY

Sebastian Schaub, DVM
Dr. med. vet. DipECVDI

HOSPITAL NAME

Rockaway Animal
Hospital

REFERRING VET

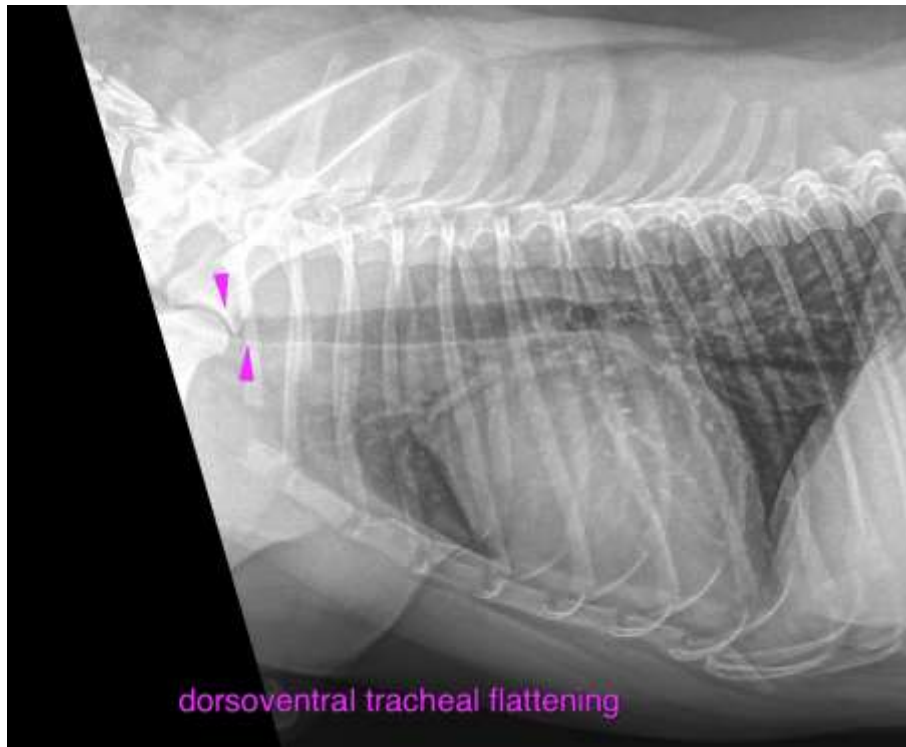
Dr. Maniar

INVOICE

48337

DATE

11-13-21



The information and recommendations provided are based on the images presented by the referring veterinarian. No evaluation can be communicated regarding pathology that was not visible in the image/video clips provided.

Thank you for this referral. If the clinical or image interpretation does not parallel your findings or if I can be of any further assistance please contact me.

Sebastian Schaub, Sebastian Schaub, DVM, Dr. med. vet. DipECVDI
sebast.schaub@gmail.com