



## PATIENT

Shilo Hain

## SPECIES

Canine

## BREED

Cattle Dog

## SEX

Mi

## AGE

1

## WEIGHT

16

## INTERPRETED BY

Sebastian Schaub, DVM  
Dr. med. vet.  
DipECVDI

## IMAGING PERFORMED BY

David

## HOSPITAL NAME

Animal Surgical Center  
- Oceanside

## REFERRING VET

Short

## INVOICE

72600

## DATE

11-12-25

## PRESENTING CLINICAL SIGNS

Intermittent R forelimb lameness

## COMPUTED TOMOGRAPHY OF THE SHOULDER AND ELBOW JOINTS

A high resolution plain CT study of the front limbs is provided for review.

## COMPUTED TOMOGRAPHIC FINDINGS

Both shoulder joints present smooth margins of the periarticular bones and the surrounding soft tissue structures are within normal limits.

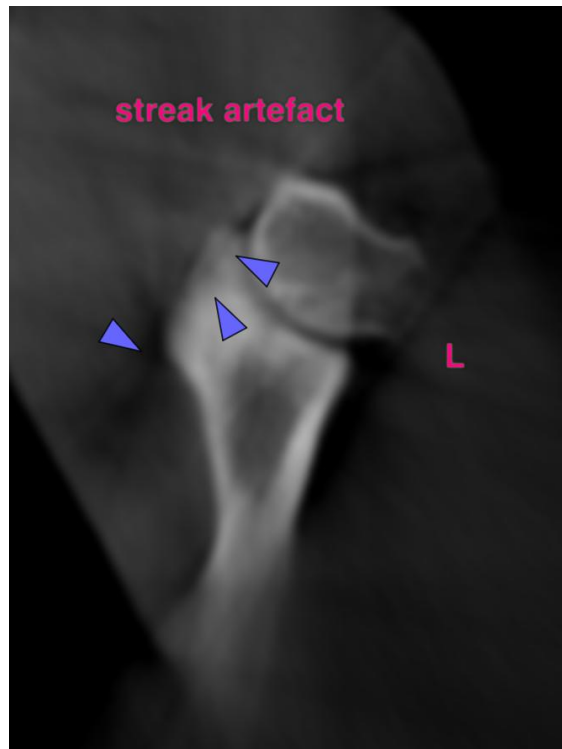
Streak artefacts are interfering with the elbow joints, L>R. The elbow joints present smooth margins of the periarticular bones. The medial coronoid process of both elbow joints is well defined and has a homogeneous density.

## COMPUTED TOMOGRAPHIC DIAGNOSIS

- Normal shoulder joints
- Normal elbow joints

## INTERPRETATION OF THE FINDINGS & FURTHER RECOMMENDATIONS

The CT study reveals no abnormalities and an underlying cause for the intermittent right front limb lameness cannot be specified. Streak artefacts reduce diagnostic value for coronoid disease, though the elbow joints show no obvious abnormalities. If clinical findings are concerning for pathology of the elbow joints, a follow up CT study of the elbow joints may be beneficial.





**PATIENT**

Shilo Hain

The information and recommendations provided are based on the images presented by the referring veterinarian/sonographer. No evaluation can be communicated regarding pathology that was not visible in the image/video clips provided.

**SPECIES**

Canine

Thank you for this referral. If the clinical or image interpretation does not parallel your findings or if I can be of any further assistance please contact me.

**BREED**

Cattle Dog

**Sebastian Schaub**, Sebastian Schaub, DVM, Dr. med. vet. DipECVDI

[info@sonopath.com](mailto:info@sonopath.com)

**SEX**

Mi

**AGE**

1

**WEIGHT**

16

**INTERPRETED BY**

Sebastian Schaub, DVM  
Dr. med. vet.  
DipECVDI

**IMAGING  
PERFORMED BY**

David

**HOSPITAL NAME**

Animal Surgical Center  
- Oceanside

**REFERRING VET**

Short

**INVOICE**

72600

**DATE**

11-12-25