



PATIENT

Iris Fonseca

SPECIES

Canine

BREED

French Bulldog

SEX

Spayed Female

AGE

7Y

WEIGHT

11.5

INTERPRETED BY

Sebastian Schaub, DVM
Dr. med. vet.
DipECVDI

IMAGING PERFORMED BY

Truscott Animal
Hospital

HOSPITAL NAME

Truscott Animal
Hospital

REFERRING VET

Dr. Medhat Mewad

INVOICE

72593

DATE

11-12-25

PRESENTING CLINICAL SIGNS

presented with chronic swelling on the left forehead, as per the owner the swelling sometimes gets very big and affects the eye, sometimes regresses but still very visible but still very visible on the left frontal sinus area need to rule out neoplasia vs osteomyelitis vs others

RADIOGRAPHIC STUDY OF THE SKULL

Radiographs of the skull in multiple image planes are provided for review.

RADIOGRAPHIC FINDINGS

The frontal bone presents an ill-defined zone with permeative osteolysis and irregular new bone formation with potential perforation of the cranial fossa. The dorsal surface of the frontal bone is perforated. The overlying soft tissues along the frontal bone are swollen.

Multiple teeth are absent.

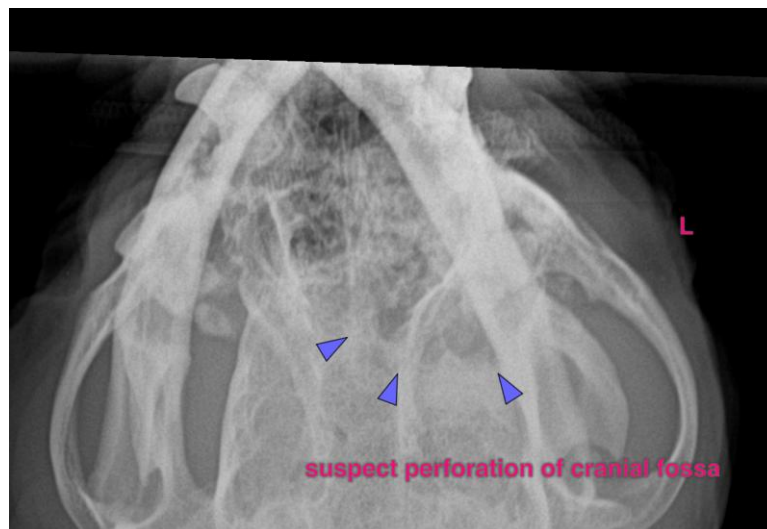
The horizontal segment of the external ear canals is narrowed.

RADIOGRAPHIC DIAGNOSIS

- Aggressive mixed osteolytic and osteoproliferative lesion left frontal bone with possible perforation of the cranial fossa
- Stenotic external ear canals
- Multiple absent teeth

INTERPRETATION OF THE FINDINGS & FURTHER RECOMMENDATIONS

Unfortunately, definitive differentiation between inflammatory process or neoplastic disease (e.g. carcinoma of the frontal sinus versus primary osseous neoplasia) by radiography is not possible. The variable size of the clinically appreciated swelling can be caused by variable degree of mucus accumulation which can be seen both with obstructive sinusitis and secondary osteomyelitis or in cases with carcinoma. The supposed perforation of the cranial fossa would increase the odds for aggressive neoplastic disease. Biopsy/FNA sampling of the lesion ± CT may allow further specification.





PATIENT

Iris Fonseca

SPECIES

Canine

BREED

French Bulldog

SEX

Spayed Female

AGE

7Y

WEIGHT

11.5

INTERPRETED BY

Sebastian Schaub, DVM
Dr. med. vet.
DipECVDI

IMAGING PERFORMED BY

Truscott Animal
Hospital

HOSPITAL NAME

Truscott Animal
Hospital

REFERRING VET

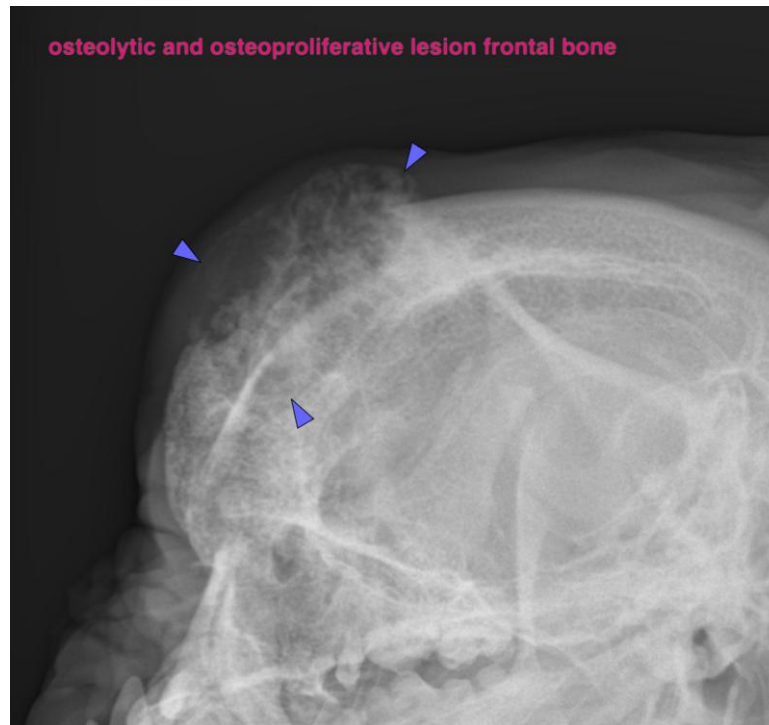
Dr. Medhat Mewad

INVOICE

72593

DATE

11-12-25



The information and recommendations provided are based on the images presented by the referring veterinarian/sonographer. No evaluation can be communicated regarding pathology that was not visible in the image/video clips provided.

Thank you for this referral. If the clinical or image interpretation does not parallel your findings or if I can be of any further assistance please contact me.

Sebastian Schaub, Sebastian Schaub, DVM, Dr. med. vet. DipECVDI
info@sonopath.com