

**PATIENT**

Cashew Millington

**PRESENTING CLINICAL SIGNS**

Patient presents for a COHAT. A survey CT of the skull with emphasis on the dental arcade is submitted for review.

Abnormal PE/Chem/CBC/UA Results: NSF

**SPECIES**

Canine

**COMPUTED TOMOGRAPHY OF THE SKULL**

A high resolution plain CT study of the skull provided for review.

**BREED**

Chihuahua

**COMPUTED TOMOGRAPHIC FINDINGS**

Triadan 105, 205, 209, 210, 301-303, 305, 401-403 and 405 present a moderate widening of the periodontal space.

**SEX**

MN

The nasal cavity presents the expected aerated spaces between thin & even conchae and turbinates with smooth mucosal lining.

Both temporomandibular joints present congruent joint spaces with even subchondral bone surfaces and are considered within normal limits.

**AGE**

5 Years, 1 Month

Both tympanic bullae are aerated, the mucosal lining is not seen, the bony wall is smooth and thin. The external ear canals are within normal limits.

**INTERPRETED BY**

Sebastian Schaub, DVM  
Dr. med. vet. DipECVDI

**COMPUTED TOMOGRAPHIC DIAGNOSIS**

- Periodontal disease 105, 205, 209, 210, 301-303, 305, 401-403 and 405

**INTERPRETATION OF THE FINDINGS & FURTHER RECOMMENDATIONS**

The CT study is consistent with periodontal disease of multiple tooth elements. A complete dental workup has already been performed.

**HOSPITAL NAME**

South Bay Animal  
Hospital

**REFERRING VET**

Ravinder Atwal, DVM,  
CCRP

**INVOICE**

48318

**DATE**

11-12-21



**PATIENT**

Cashew Millington

**SPECIES**

Canine

**BREED**

Chihuahua

**SEX**

MN

**AGE**

5 Years, 1 Month

**INTERPRETED BY**

Sebastian Schaub, DVM  
Dr. med. vet. DipECVDI

**HOSPITAL NAME**

South Bay Animal  
Hospital

**REFERRING VET**

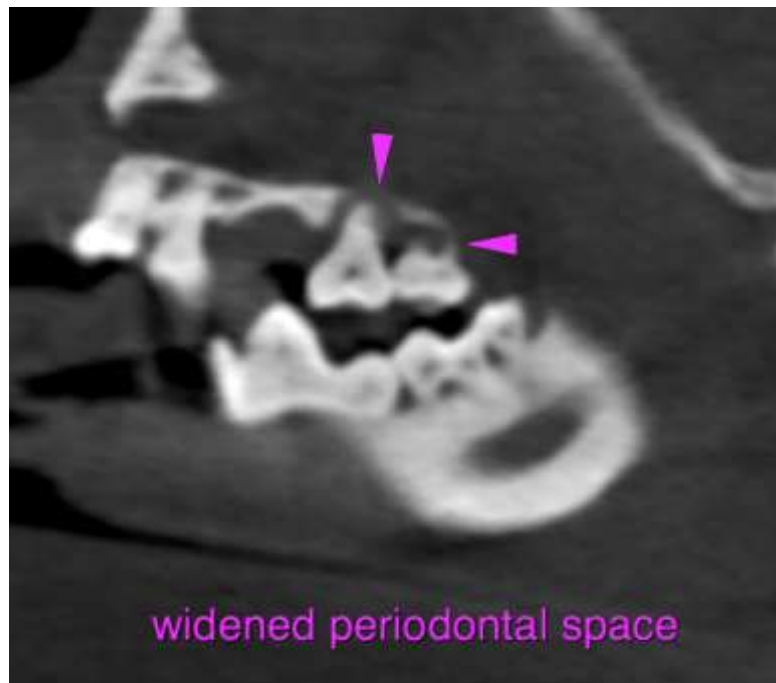
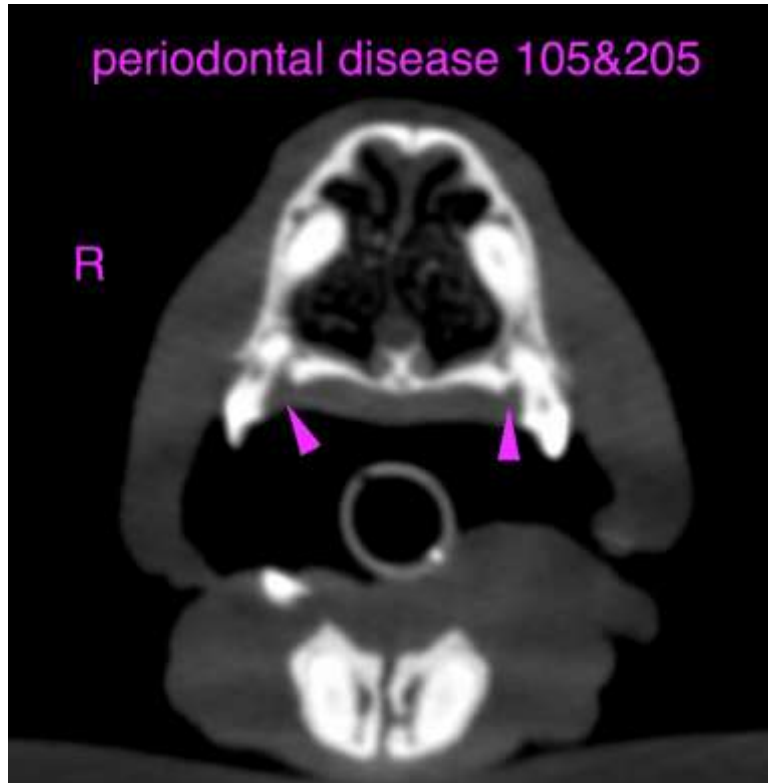
Ravinder Atwal, DVM,  
CCRP

**INVOICE**

48318

**DATE**

11-12-21





**PATIENT**

Cashew Millington

The information and recommendations provided are based on the images presented by the referring veterinarian. No evaluation can be communicated regarding pathology that was not visible in the image/video clips provided.

**SPECIES**

Canine

Thank you for this referral. If the clinical or image interpretation does not parallel your findings or if I can be of any further assistance please contact me.

**BREED**

Chihuahua

**Sebastian Schaub**, Sebastian Schaub, DVM, Dr. med. vet. DipECVDI  
sebast.schaub@gmail.com

**SEX**

MN

**AGE**

5 Years, 1 Month

**INTERPRETED BY**

Sebastian Schaub, DVM  
Dr. med. vet. DipECVDI

**HOSPITAL NAME**

South Bay Animal  
Hospital

**REFERRING VET**

Ravinder Atwal, DVM,  
CCRP

**INVOICE**

48318

**DATE**

11-12-21