



PATIENT

Yumi Goisman

SPECIES

Canine

BREED

Belgian Sheepdog

SEX

Spayed Female

AGE

11M

WEIGHT

23.5

INTERPRETED BY

Sebastian Schaub, DVM
Dr. med. vet.
DipECVDI

IMAGING PERFORMED BY

Hector

HOSPITAL NAME

CARE Surgery Center

REFERRING VET

Dr. Seth Bleakley

INVOICE

72581

DATE

11-11-25

PRESENTING CLINICAL SIGNS

Elbow dysplasia with incongruity, right worse than left

COMPUTED TOMOGRAPHY OF THE ELBOW JOINTS

A high resolution plain CT study of the elbow joints is provided for review.

COMPUTED TOMOGRAPHIC FINDINGS

The periarticular bones of the left elbow joint present very mild osteophyte new bone formation. The cranial tip of the medial coronoid process of the left elbow joint is mildly irregular with a mild heterogeneous density. The surrounding soft tissue structures of the left elbow joint are unremarkable.

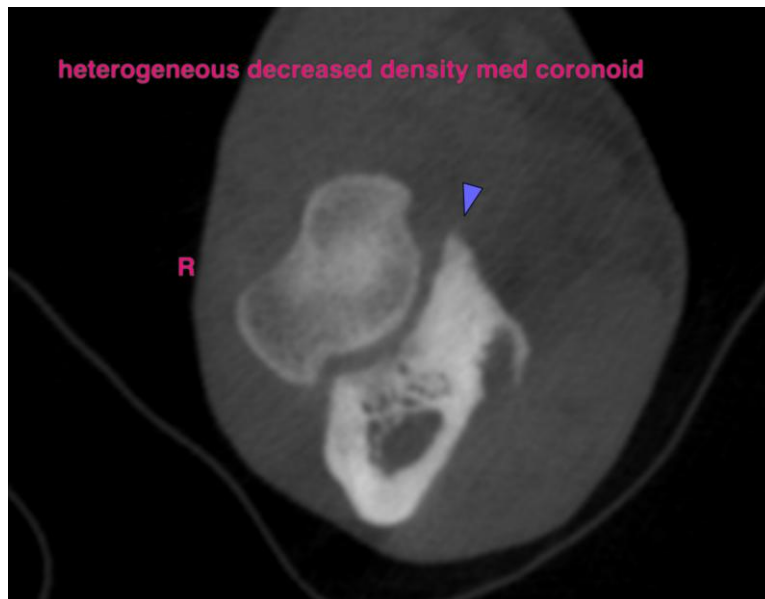
The periarticular bones of the right elbow joint present moderate osteophyte new bone formation. The medial coronoid process of the right elbow joint is irregular and has a heterogeneous density. Isolated mineralizations are seen cranial and caudal to the supratrochlear foramen. The joint space of the right elbow joint is mildly incongruent.

COMPUTED TOMOGRAPHIC DIAGNOSIS

- Coronoid disease elbow joint bilaterally, R>L
- Osteoarthritis elbow joints bilaterally, R>>>L
- Incongruity right elbow joint
- Metaplasia joint capsule right elbow joint

INTERPRETATION OF THE FINDINGS & FURTHER RECOMMENDATIONS

The CT study is consistent with bilateral elbow dysplasia and secondary degenerative joint disease of the elbow joints, R>>>L. Arthroscopy/arthrotomy would be ideal to revise the elbow joints and remove the osseous fragment/nonvital tip of the medial coronoid process to avoid further damage.





PATIENT

Yumi Goisman

SPECIES

Canine

BREED

Belgian Sheepdog

SEX

Spayed Female

AGE

11M

WEIGHT

23.5

INTERPRETED BY

Sebastian Schaub, DVM
Dr. med. vet.
DipECVDI

IMAGING PERFORMED BY

Hector

HOSPITAL NAME

CARE Surgery Center

REFERRING VET

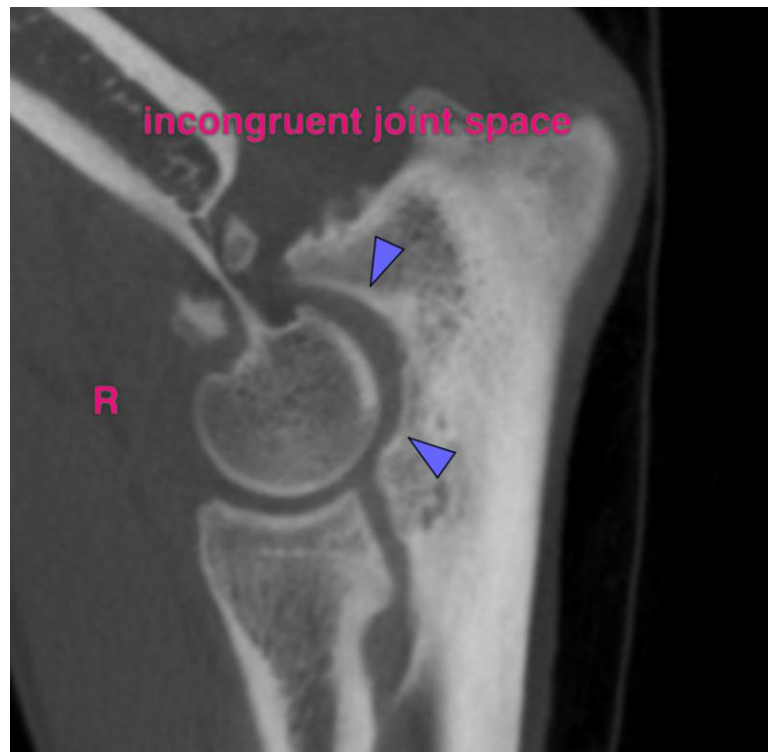
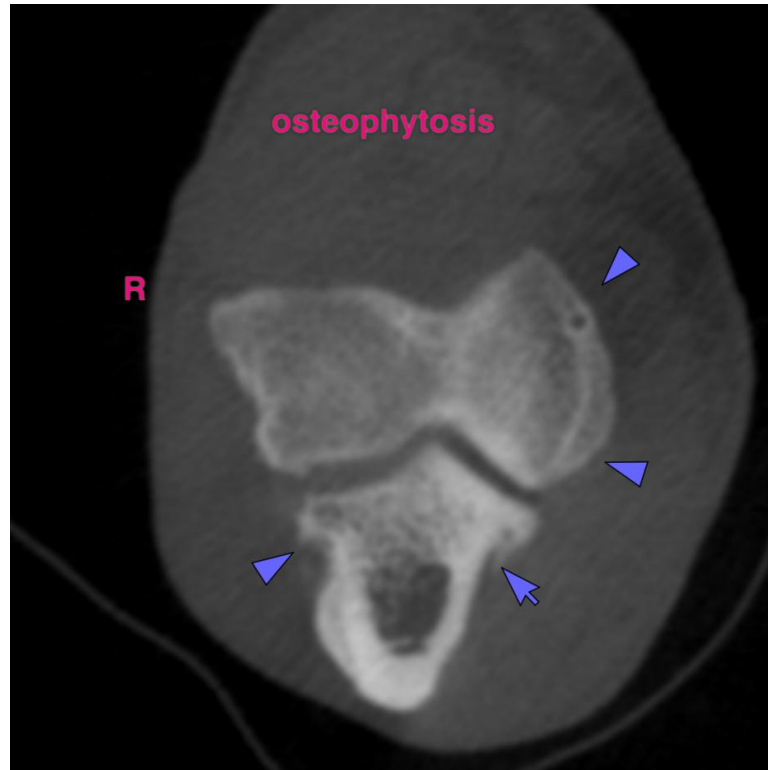
Dr. Seth Bleakley

INVOICE

72581

DATE

11-11-25





PATIENT

Yumi Goisman

SPECIES

Canine

BREED

Belgian Sheepdog

SEX

Spayed Female

AGE

11M

WEIGHT

23.5

INTERPRETED BY

Sebastian Schaub, DVM
Dr. med. vet.
DipECVDI

IMAGING PERFORMED BY

Hector

HOSPITAL NAME

CARE Surgery Center

REFERRING VET

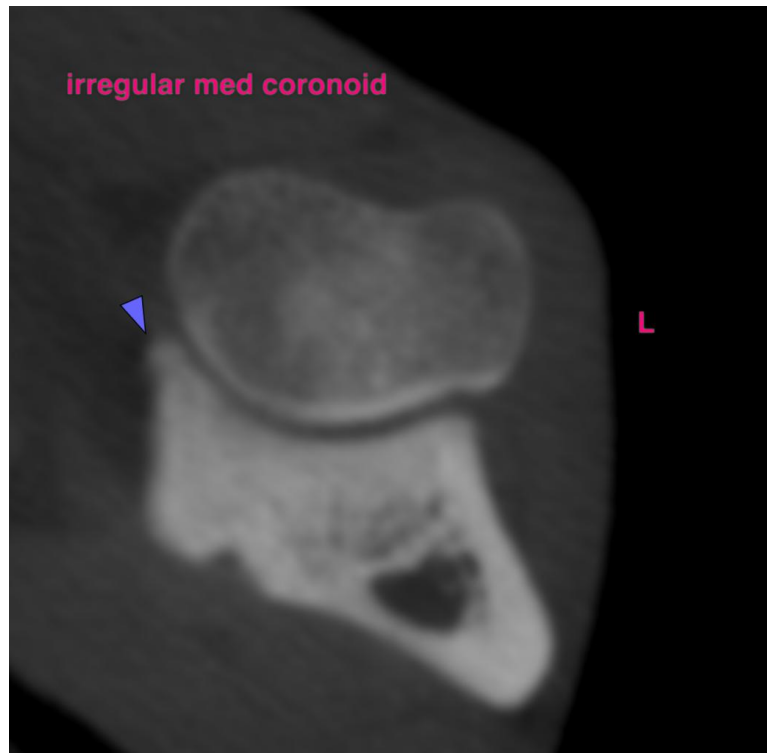
Dr. Seth Bleakley

INVOICE

72581

DATE

11-11-25



The information and recommendations provided are based on the images presented by the referring veterinarian/sonographer. No evaluation can be communicated regarding pathology that was not visible in the image/video clips provided.

Thank you for this referral. If the clinical or image interpretation does not parallel your findings or if I can be of any further assistance please contact me.

Sebastian Schaub, Sebastian Schaub, DVM, Dr. med. vet. DipECVDI
info@sonopath.com