



**PATIENT PRESENTING CLINICAL SIGNS**

Crosby Hook History: Presented for 3-4 days of a progressive pelvic limb paresis. No history of trauma, but he does play rough with the other bulldog in the house. He hasn't shown any sign of pain, just weakness.

**SPECIES** Abnormal PE/Chem/CBC/UA Results: Pelvic limb paresis. Worse on the L side

Canine **RADIOGRAPHIC STUDY OF THE LUMBAR SPINE**

Radiographs of the lumbar spine in two imaging planes are provided for review.

**BREED**

English Bulldog

**RADIOGRAPHIC FINDINGS**

The growth plates are age related open.

**SEX**

Male

L1 is moderately shortened and the intervertebral disc spaces T13/L1 and L1/L2 are moderately narrowed.

The sacrum and caudate spine present a breed specific malformation with block vertebra formation.

**AGE**

6 Months

**RADIOGRAPHIC DIAGNOSIS**

- Hemivertebra L1

**INTERPRETED BY**

Sebastian Schaub,  
DVM Dr. med. vet.  
DipECVDI

**INTERPRETATION OF THE FINDINGS & FURTHER RECOMMENDATIONS**

The radiographic study presents no specific abnormality, explaining the progressive paraparesis. Cross-sectional imaging either by CT including a myelographic CT study or MRI can be used as advanced diagnostic tests and to screen for pathology such as subarachnoid diverticulum or spinal canal stenosis.

**HOSPITAL NAME**

Pinebrook AH

**REFERRING VET**

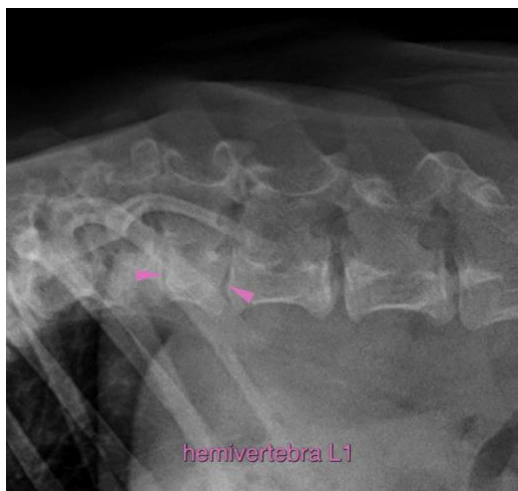
Jillian Burchett

**INVOICE**

14276

**DATE**

11/11/21





**PATIENT**

Crosby Hook

**The information and recommendations provided are based on the images presented by the referring veterinarian. No evaluation can be communicated regarding pathology that was not visible in the image/video clips provided.**

**SPECIES**

Canine

Thank you for this referral. If the clinical or image interpretation does not parallel your findings or if I can be of any further assistance please contact me.

**Sebastian Schaub**, Sebastian Schaub, DVM, Dr. med. vet. DipECVDI  
sebast.schaub@gmail.com

**BREED**

English Bulldog

**SEX**

Male

**AGE**

6 Months

**INTERPRETED BY**

Sebastian Schaub,  
DVM Dr. med. vet.  
DipECVDI

**HOSPITAL NAME**

Pinebrook AH

**REFERRING VET**

Jillian Burchett

**INVOICE**

14276

**DATE**

11/11/21