

**PATIENT**

Cypres Snow

**SPECIES**

Feline

**BREED**

Domestic Shorthair

**SEX**

Neutered Male

**AGE**

12 Years

**INTERPRETED BY**Sebastian Schaub, DVM  
Dr. med. vet. DipECVDI**HOSPITAL NAME**Truscott Animal  
Hospital**REFERRING VET**

Dr. Medhat Meawad

**INVOICE**

54910

**DATE**

11-1-22

**PRESENTING CLINICAL SIGNS**

Torn nail originally in Sept, would not heal and continued to swell, removed the first two digits of the third toe on the right paw, pathology results confirmed carcinoma (sqc), recommended to do radiographs on the lungs and other digits.

Abnormal PE/Chem/CBC/UA Results: BW from September attached Pathology from Oct attached with results stating carcinoma.

**RADIOGRAPHIC STUDY OF THE THORAX**

Radiographs of the thorax in three imaging planes are provided for review.

**RADIOGRAPHIC FINDINGS**

A moderate amount of soft tissue material is seen in the pleural cavity. The lung lobes are retracted from the thoracic wall and pleural fissure lines are visible.

Multifocal throughout the lung parenchyma well-defined roundish nodular lesions of varying size are appreciated. In the lateral view, a roundish mass is superimposed on caudal lung field, measuring approximately 4 cm in size.

The surrounding bony structures are within normal limits.

The extrathoracic soft tissues present homogeneous without abnormalities.

The trachea is normal in diameter and presents the anticipated course. The luminal outline of the trachea is smooth.

**RADIOGRAPHIC DIAGNOSIS**

- Pulmonary mass with dystrophic mineralization
- Structured nodular interstitial lung pattern
- Moderate pleural effusion

**INTERPRETATION OF THE FINDINGS & FURTHER RECOMMENDATIONS**

The radiographic changes in combination with the history of aggressive lesions of the digits is compatible with feline lung-digit syndrome due to primary pulmonary carcinoma with metastatic spread to the phalanges. The pleural effusion is likely paraneoplastic.



**PATIENT**

Cypres Snow

**SPECIES**

Feline

**BREED**

Domestic Shorthair

**SEX**

Neutered Male

**AGE**

12 Years

**INTERPRETED BY**

Sebastian Schaub, DVM  
Dr. med. vet. DipECVDI

**HOSPITAL NAME**

Truscott Animal  
Hospital

**REFERRING VET**

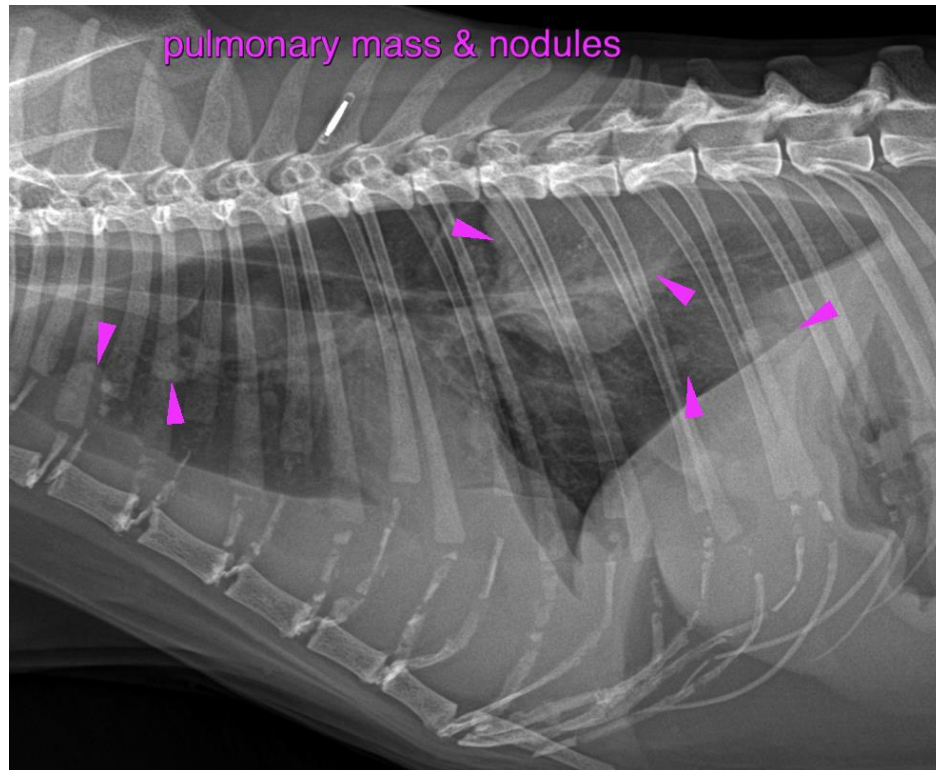
Dr. Medhat Meawad

**INVOICE**

54910

**DATE**

11-1-22



The information and recommendations provided are based on the images presented by the referring veterinarian/sonographer. No evaluation can be communicated regarding pathology that was not visible in the image/video clips provided.

Thank you for this referral. If the clinical or image interpretation does not parallel your findings or if I can be of any further assistance please contact me.

**Sebastian Schaub**, Sebastian Schaub, DVM, Dr. med. vet. DipECVDI  
sebast.schaub@gmail.com