

**PATIENT**

Lucie Szybowicz

PRESENTING CLINICAL SIGNS

Patient presented for acute lameness on left front, concerned with the possible development of osteosarcoma.

SPECIES

Canine

RADIOGRAPHIC STUDY OF THE SHOULDER JOINTS

Radiographs of the shoulder joints are provided for review.

BREED

Mixed

RADIOGRAPHIC FINDINGS

The osseous margins of the right shoulder joint are smooth and the surrounding soft tissue structures present no abnormalities.

SEX

Spayed Female

In the caudal aspect of the left proximal humeral metaphysis and diaphysis an ill-defined zone with permeative osteolytic lesions is visible and immature periosteal new bone formation is seen at the caudal aspect of the left proximal humeral metaphysis & diaphysis. The periarticular bones of the left shoulder joint present mild osteophyte new bone formation.

RADIOGRAPHIC DIAGNOSIS

- Monostotic aggressive osteolytic lesion left proximal humerus
- Mild degenerative osteoarthritis left shoulder joint
- Normal right shoulder joint

AGE

12 Years

INTERPRETED BY

Sebastian Schaub, DVM
Dr. med. vet. DipECVDI

INTERPRETATION OF THE FINDINGS & FURTHER RECOMMENDATIONS

The findings are most consistent with primary osseous neoplasia of the left proximal humerus, such as osteosarcoma, chondrosarcoma, hemangiosarcoma, other. Theoretically osteomyelitis – e.g. mycotic – is a potential, but considered unlikely. FNA sampling or bone biopsy of the left proximal humerus can be performed to confirm the diagnosis.

HOSPITAL NAME

Neighborhood Pet
Health Center

Recommend full tumor staging.

REFERRING VET

Russell Johnson

INVOICE

48149

DATE

11-1-21



PATIENT

Lucie Szybowicz

SPECIES

Canine

BREED

Mixed

SEX

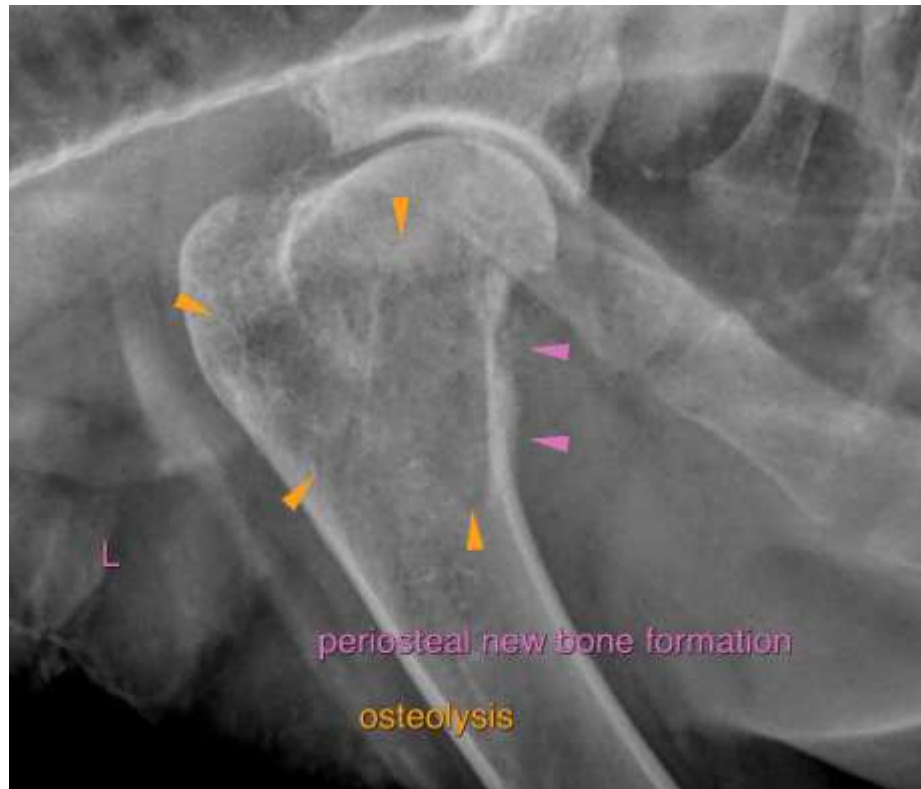
Spayed Female

AGE

12 Years

INTERPRETED BY

Sebastian Schaub, DVM
Dr. med. vet. DipECVDI



HOSPITAL NAME

Neighborhood Pet
Health Center

REFERRING VET

Russell Johnson

INVOICE

48149

DATE

11-1-21

The information and recommendations provided are based on the images presented by the referring veterinarian. No evaluation can be communicated regarding pathology that was not visible in the image/video clips provided.

Thank you for this referral. If the clinical or image interpretation does not parallel your findings or if I can be of any further assistance please contact me.

Sebastian Schaub, Sebastian Schaub, DVM, Dr. med. vet. DipECVDI
sebast.schaub@gmail.com